

Formation, structure, and function of extra-skeletal bones in mammals

ABSTRACT

This review describes the formation, structure, and function of bony compartments in antlers, horns, ossicones, osteo-derm and the os penis/os clitoris (collectively referred to herein as AHOOO structures) in extant mammals. AHOOOs are extra-skeletal bones that originate from subcutaneous (dermal) tissues in a wide variety of mammals, and this review elaborates on the co-development of the bone and skin in these structures. During foetal stages, primordial cells for the bony compartments arise in subcutaneous tissues. The epithelial–mesenchymal transition is assumed to play a key role in the differentiation of bone, cartilage, skin and other tissues in AHOOO structures. AHOOO ossification takes place after skeletal bone formation, and may depend on sexual maturity. Skin keratinization occurs in tandem with ossification and may be under the control of androgens. Both endochondral and intramembranous ossification participate in bony compartment formation. There is variation in gradients of density in different AHOOO structures. These gradients, which vary according to function and species, primarily reduce mechanical stress. Anchorage of AHOOOs to their surrounding tissues fortifies these structures and is accomplished by bone–bone fusion and Sharpey fibres. The presence of the integument is essential for the protection and function of the bony compartments. Three major functions can be attributed to AHOOOs: mechanical, visual, and thermoregulatory. This review provides the first extensive comparative description of the skeletal and integumentary systems of AHOOOs in a variety of mammals.

Key words: antlers, horns, ossicones, osteo-derm, os penis/os clitoris, integumentary system, formation, structure, function, epithelial–mesenchymal transition

CONTENTS

I. Introduction	2
II. Antlers	3
(1) Development	3
(a) Pedicle formation	3
(b) The antler cycle	4
(i) Wet antler	5
(ii) Hard antler	5
(2) Structure and function	5
(3) Reindeer antlers	6
(a) Formation	6
(b) Function	6
III. Horns	6
(1) Formation	7
(a) Keratinization and ossification	7
(b) Horn generative region	8
(2) Structure	9
(a) The integument	9
(b) The core bone	9

(c) Pneumatization	9
(3) Function	10
IV. Pronghorns	10
(1) Formation	10
(2) Structure	10
(3) Function	11
V. Ossicones	12
(1) The giraffe	12
(a) Formation	12
(b) Structure and function	13
(2) The okapi	13
(a) Formation	13
(b) Structure and function	13
VI. Armadillo osteoderm	14
(1) Formation	14
(2) Structure	15
(a) Osteoderm	15
(b) Integument	16
(3) Functions	16
(a) Mechanical features	16
(b) Thermoregulatory properties	16
(c) Visual impact	16
(4) Sexual differences	17
(5) Other armoured structures in mammals	17
VII. Penis bone/clitoris bone	17
(1) Formation	18
(2) Structure	18
(a) Interspecific variation	18
(b) The bony compartment	19
(c) Integument	20
(3) Function	20
VIII. Other extra-skeletal mineralized tissues	20
(1) Heart bone (os cordis)	20
(2) Sesamoids	21
(3) Rhinoceros horns	21
(a) Formation	21
(b) Structure	21
(c) Function	22
IX. The development of extra-skeletal bones	22
(1) Formation of the bone and surrounding tissues	22
(a) Horns, ossicones and antler pedicle	22
(b) Events in the skin and underlying tissues	23
(i) Skin	23
(ii) Epithelial–mesenchymal transition	23
(2) Postnatal ossification	23
X. Future directions	24
XI. Conclusions	24
XII. References	25
XIII. Supporting information	34

I. INTRODUCTION

Bones and teeth are hard mineralized tissues consisting of cells, proteins and minerals (mainly hydroxyapatite). Bones serve structural, mechanical, endocrinal, haematopoietic and homeostatic functions (Deng & Liu, 2005; Marcus *et al.*, 2010; Ungar, 2010; Kardong, 2015). During embryonic stages, bone arises from the neural crest and/or

mesoderm (Hall, 2008; Maruyama, 2011; Sadler, 2012) *via* two mechanisms: (i) in endochondral ossification, cartilaginous tissue (produced by mesenchymal cells) is converted to ossified tissue. This mechanism is involved in longitudinal growth of the long bones (such as the femur and humerus) and in formation of the vertebrae; (ii) in intramembranous ossification, mesenchymal cells directly produce osteoblasts which then form ossified tissue. This mechanism generates

most parts of the skull and is involved in circumferential growth of the long bones (Cowin, 2001; Ross, Kaye & Pawlina, 2002; Deng & Liu, 2005; Dwek, 2010; Recce *et al.*, 2015). A third mechanism, which is less ubiquitous than endochondral and intramembranous ossification, is metaplastic bone formation. Metaplastic ossification is characterized by mineralization of cells in the dermis, and occurs in the absence of osteoblasts (Vickaryous & Sire, 2009). Metaplastic ossification occurs naturally in the dermis of some tetrapods (e.g. some amphibians and in reptilian osteoderm) (Quinzio & Fabrezi, 2012; Rice *et al.*, 2015; Griffing *et al.*, 2018). In humans, dogs, and cats, metaplastic ossification is usually regarded as a pathological symptom, occurring when pluripotent stem cells of the cutaneous tissue, under the influence of growth factors such as inflammatory cytokines, promote ossification *in situ* (ectopic bone) (Nakagawa & Tagami, 1997; Frazier *et al.*, 1998; Thompson, 2007; Dubansky & Dubansky, 2018). However, some evidence suggests that particular areas of skeletal bone may be formed *via* metaplastic ossification during normal development (Haines & Mohuiddin, 1968; Benjamin, Evans & Copp, 1986; Heck *et al.*, 2019).

The external surfaces of bones are covered by a thin layer called the periosteum, which has osteogenic properties. This layer also facilitates bone attachment to the surrounding soft tissues. Collagen fibres, which are embedded into the external surface of the bone, go through the periosteum to reach and embed into the adjacent soft tissue. These fibres are called Sharpey fibres and have a crucial role in bone anchorage. Similar fibres in the periodontal ligaments attach the teeth to the upper and lower jaws (Cowin, 2001; Ross *et al.*, 2002; Dwek, 2010; Nasoori *et al.*, 2013; Niemiec, 2013; Hill, 2019).

This review elaborates on the formation, structure and function of antlers, horns, ossicones, osteoderm and the os penis/os clitoris (collectively referred to herein as AHOOO structures) which occur naturally in mammals. AHOOOs are bony compartments that are formed separately from skeletal bones. Based on existing data from extant mammals, the formation of these bony structures is associated with structural changes to the integument. The different AHOOOs share similarities in formation, structure and function. According to a classification derived by Hall (2010), the vertebrate skeleton can be divided into five categories: (i) axial skeleton; (ii) appendicular skeleton; (iii) craniofacial skeleton; (iv) dermal skeleton; and (v) extra-skeletal system. In this classification AHOOOs are extra-skeletal bones with a subcutaneous (dermal) origin.

This review does not consider the evolution of AHOOOs, and future studies could explore the evolutionary links between taxa that possess these extra-skeletal bony structures. The evolution of 'headgear', osteoderm, and genital bones have been addressed previously and interested readers are referred to Davis, Brakora & Lee (2011) and Wang *et al.* (2019) for antlers/headgear, Vickaryous & Sire (2009) and Ciancio *et al.* (2019) for osteoderm, and Ramm (2007),

Schultz *et al.* (2016a,b) and Lough-Stevens, Schultz & Dean (2018) for genital bones.

II. ANTLERS

Antlers are branched bony structures that occur in the Cervidae (deer). Antlers occur in males, but are absent in females, with the exception of reindeer (*Rangifer tarandus*; see Section II.3) in which both sexes possess antlers (Lincoln, 1994; Hall, 2015). Antler development is under the control of androgens (Price *et al.*, 2005; Kierdorf, Kierdorf & Schwartz, 2007). After puberty, a pair of bony cylindrical structures (pedicles) appears on the frontal region of the skull, from which the antlers subsequently develop (see online Supporting information, Figs S1 and S2). Cervids undergo an annual cycle of antler growth and casting (shedding) which is governed by hormonal changes and environmental cues (Yamauchi & Matsuura, 2009; Ungerfeld & Canabal, 2014; Hall, 2015).

(I) Development

(a) Pedicle formation

The pedicle is a permanent bony structure upon which the antler begins to grow, and also is the site from which the mature antler is shed (cast). The pedicle forms in response to androgens in male deer. However, some male deer can remain antlerless (hummels), often as a result of malnutrition and insufficient levels of insulin-like growth factor 1 (IGF1) (Li & Suttie, 1996; Kierdorf & Kierdorf, 2002; Li *et al.*, 2003).

During the foetal stage in male red deer (*Cervus elaphus*), the pedicle primordia forms at the future site of the pedicle, first becoming visible at around 60 days of gestation. It is distinctly prominent in a 100-day male foetus, but later on, it becomes inconspicuous due to the differential growth of the peripheral tissues. By contrast, the primordium in the female foetus is relatively small and does not change as the foetus develops (Lincoln, 1973; Li *et al.*, 2014).

After birth but before sexual maturity, a primitive bony protrusion composed of cancellous bone is formed on the frontal bone: the frontal lateral crest (Li & Suttie, 1994) or external frontal crest (Kierdorf & Kierdorf, 2002). The primitive bud, which will later form the pedicle, is present below the antlerogenic periosteum (AP) which is beneath the subcutaneous loose connective tissue, dermis and epidermis, from the bottom to top (Fig. 1A). In males, this area protrudes and contains numerous osteoblasts, while in females it is either smooth and composed of compact bone lacking osteoblasts or is a slight protrusion composed of cancellous bone with few osteoblasts. The protrusions are formed by intramembranous ossification and in males will continue to develop into the pedicle. Upon maturity a process of endochondral ossification on the surface of the pedicle will form the antler (Kierdorf *et al.*, 1994, 1995; Li & Suttie, 1994, 2001; Kierdorf & Kierdorf, 2002; Li *et al.*, 2003) (Fig. 1C).

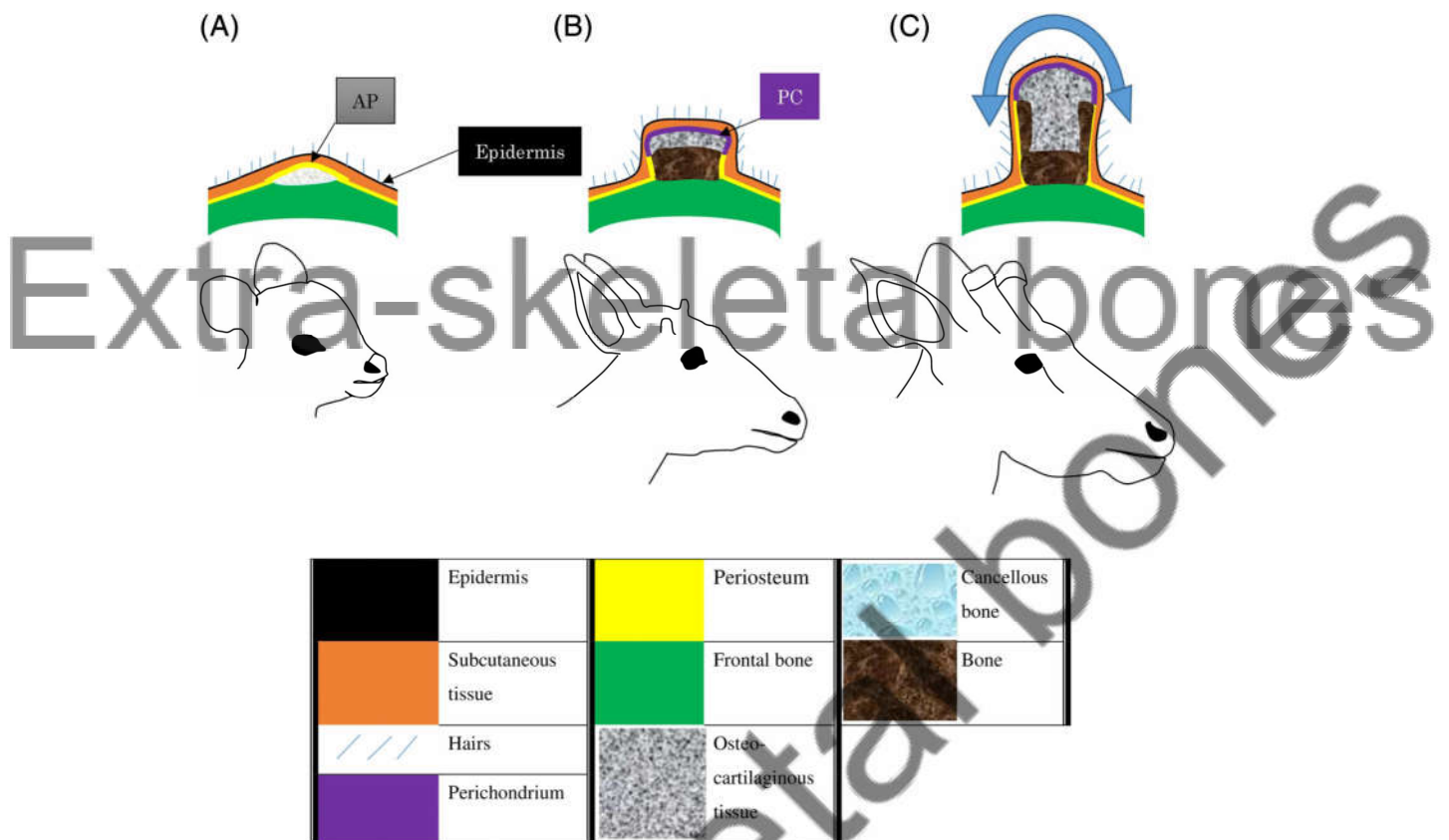


Fig. 1. Lateral view of the skull at the region of the pedicle to show stages in pedicle and antler development in male red deer (*Cervus elaphus*). (A) At an age of 3–4 months a region of cancellous bone is generated on the frontal lateral crest under the antlerogenic periosteum (AP) via intramembranous ossification. (B) By 8 months the pedicle becomes visible and is about 2 cm in height. While the base of the pedicle is composed of bone, the upper parts contain cartilaginous tissue generated by perichondrium (PC). The chondrocytes are ossified from the upper to lower side and from the margin to the centre. (C) In the adult the same ossification process leads to antler formation (blue double arrow). Skin transformation produces velvet on the antler integument.

The pedicle and antler are formed beneath the AP. In males the thickness of the AP is significantly greater than the surrounding periosteum on the skull, mainly due to thicker cellular layers. This difference is not present in females (Kierdorf *et al.*, 1994; Li & Suttie, 1994; Gao *et al.*, 2012). The external (contra-pedicle) side of the AP must be in contact with the subcutaneous tissue to bring about pedicle formation; a lack of such interaction prevents pedicle growth (Li *et al.*, 2008). IGF1 and body mass also have roles in pedicle and antler development (Suttie *et al.*, 1989; Schams *et al.*, 1992; Li *et al.*, 2003).

The pedicle of the male red deer becomes palpable after 6 months of age. At around 8 months of age, when the pedicle is about 2 cm, it becomes visible on the skull. It needs to reach approximately 5–6 cm in height to allow the antler to develop (Li & Suttie, 1994, 2001; Li *et al.*, 2003). The first antler formation is a continuation of pedicle growth. A distinguishing feature of antler formation is transformation of the skin: from the beginning of the antler (distal pedicle and proximal antler boundary) to the upper end, the skin is less hairy than the surrounding skin on the head, and is termed

‘velvet’ (Fig. S3). The velvet undergoes microscopic alterations (see Section II.1*b.i*). Despite these visible integumentary alterations, there are almost no internal changes in the bony structure: the bony compartment of the pedicle and antler are homogenous and cannot be differentiated microscopically (Goss & Powel, 1985; Li & Suttie, 1994, 2001; Kierdorf *et al.*, 1995).

Testosterone is a key regulator of pedicle and antler formation. Castration before the growth of the antler inhibits its eruption and development, and exogenous testosterone allows antler development to resume. Androgens can even induce pedicle and antler formation in females (Li *et al.*, 2003; Kierdorf & Kierdorf, 2011; Hall, 2015).

(b) The antler cycle

Three main regions are involved in the development and architecture of the antler: (i) the antler velvet; (ii) the cambium layer (periosteum) located below the velvet on the surface of the antler; (iii) the pedicle (Kierdorf *et al.*, 2007; Li

et al., 2007b; Gao *et al.*, 2012). The life of the antler can be divided into two stages: the wet antler and the hard antler.

(i) *Wet antler.* The period in which velvet is present on the antlers, i.e. the time from budding to maximum growth, is referred to as the wet antler (Lincoln, 1994; Price *et al.*, 2005). The outer layer of the velvet has hair and sebaceous glands but lacks sweat glands and pili muscles. The velvet in pampas deer (*Ozotoceros bezoarticus*) consists of four layers: stratum basale, st. spinosum, st. granulosum, and st. corneum, the latter of which is highly keratinized. The underlying layers of the velvet are highly vascularized and contain neurons and mesenchymal stem cells which contribute to antler osteogenesis (Li & Suttie, 2001; Kierdorf & Kierdorf, 2002; Stéger *et al.*, 2010; Bielli *et al.*, 2017). Blood flow in the velvet is crucial for antler growth, and occlusion of the blood supply can prevent antlerogenesis (Hove & Steen, 1978; Weilburg, 1996). Antlerogenesis takes place below the velvet by two mechanisms: (i) endochondral ossification and (ii) intramembranous ossification. Endochondral ossification originates from a growth-plate-like region under the velvet that consists of mesenchymal stem cells. This zone (also called the perichondrium) is present in the upper (distal) parts of the growing antler and generates highly vascularized cartilaginous tissue. The copious blood supply allows rapid longitudinal growth (≈ 2 cm per day) (Price *et al.*, 2005; Krauss *et al.*, 2011; Gao *et al.*, 2012; Hall, 2015; Zhang *et al.*, 2017). The chondrocytes eventually are mineralized, removed, and substituted with osteoblasts. Subsequently, osteons are formed and lamellar (compact) bone appears. However, in the medullary areas, the cancellous bone is prominent (Fig. 1C) (Cegielski *et al.*, 2009; Krauss *et al.*, 2011; Ungerfeld & Canabal, 2014). Intramembranous (direct) ossification originates from the periosteum in the lower part of the antler beam only. This occurs on the surface of the antler under the velvet, in an area named the 'sub-velvet' or 'sleeve' bone. Histologically, this is compact bone and it develops circumferentially (Kierdorf *et al.*, 2007; Krauss *et al.*, 2011; Gomez *et al.*, 2013) (Fig. 1C). Antler osteogenesis is a rapid process that takes up a large amount of minerals from the skeleton (e.g. the ribs and vertebrae), which can lead to a transient physiological osteoporosis (Price *et al.*, 2005; Stéger *et al.*, 2010; Hall, 2015; Landete-Castillejos *et al.*, 2019).

The presence of skin on the pedicle is necessary for development of the antler, whereas the antler itself can continue to grow experimentally without the velvet. Isolation of the pedicle surface from the overlying skin causes the antler to fail to develop. However, if the pedicle skin and the pedicle remain in contact, the antler can develop even without its velvet layer (Kierdorf *et al.*, 2007; Li *et al.*, 2007b). Interestingly, when the antler grows experimentally without the velvet, its surface is covered with a connective tissue which contains blood vessels and a full periosteum (Li *et al.*, 2007b).

The gene expression, protein synthesis, and molecular pathways that participate in antlerogenesis have been studied in detail in recent years. These investigations show that antlerogenesis and bone formation/regeneration share many similarities, particularly in recruiting mesenchymal stem cells

(Li *et al.*, 2012; Yao *et al.*, 2018, 2019; Dong *et al.*, 2019; Ba *et al.*, 2019a,b).

Rapid growth of the antler is due to the presence of the velvet, which is enriched with blood vessels and mesenchymal cells. By contrast, there is little information available regarding growth of the velvet. It was proposed that velvet growth occurs in response to mechanical pressure from the underlying pedicle and antler (Li & Suttie, 2001). When the pedicle skin is separated from the antler, it shows little dorsal growth (Li *et al.*, 2007a), implying that velvet has poor potential for self-extension. Generally, skin has an enormous capacity for extension in response to stretching forces exerted from underlying tissues/masses (Radovan, 1982; Zeng *et al.*, 2003; Tepole, Gosain & Kuhl, 2012; Zhou *et al.*, 2015; Tepole *et al.*, 2016). This skin expansion results from increased keratinocyte mitosis and synthesis of dermal extracellular matrix proteins (Zöllner *et al.*, 2013). Angiogenic features of velvet may facilitate its expansion (Coates, Haines & Suttie, 2011), but further investigations are required to reveal the processes involved in velvet expansion during antler development.

(ii) *Hard antler.* Exfoliation of the velvet from the antler surface takes place in response to an elevation in plasma testosterone levels, leaving behind a bare bony structure without the periosteum (Kierdorf *et al.*, 2007; Yamauchi & Matsuura, 2009; Kierdorf & Kierdorf, 2011). Absence of the velvet, which is the main blood supplier, culminates in the antler's ischemic 'death' (Gomez *et al.*, 2013; Ungerfeld & Canabal, 2014; Bielli *et al.*, 2017; Landete-Castillejos *et al.*, 2019). The antlers are then sturdy enough to be used in the rut, during which plasma testosterone levels remain high (Lincoln, 1994; Yamauchi & Matsuura, 2009; Gomez *et al.*, 2013). After the rut, when plasma testosterone levels decline, osteoclasts are activated between the pedicle and the base of the antler, followed by rapid casting (Price *et al.*, 2005; Kierdorf *et al.*, 2007, 2013; Hall, 2015).

The annual cycle of antler replacement gives them a 'deciduous' feature (Lincoln, 1994; Kierdorf *et al.*, 2013). Such regular replacement cycles of mineralized structures are also found in polyphiodont mammals such as the manatee (*Trichechus* spp.) (Ronald, Selley & Amoroso, 1978; Cimino, 2013), silvery mole-rat (*Heliophobius argenteocinereus*) (Rodrigues *et al.*, 2011), and pygmy rock wallaby (*Petrogale concinna*) (Renvoisé & Michon, 2014; Tucker & Fraser, 2014), all of which have regular tooth replacement. The stem cell niche in the dental lamina participates in tooth replacement in polyphiodonts (Handrigan, Leung & Richman, 2010; Wu *et al.*, 2013; Renvoisé & Michon, 2014). Interestingly, the potential for repeated antlerogenesis is also due to the presence of stem cells, in this case residing in the velvet and pedicle (Kierdorf *et al.*, 2007; Li *et al.*, 2014; Li & Chu, 2016).

(2) Structure and function

Antler size varies among deer species ranging from short [e.g. 7.5 cm in pudu deer (*Pudu pudu*)] to long [e.g. 150 cm in elk (*Cervus canadensis*)] (Clutton-Brock, Albon & Harvey,

1980; Price *et al.*, 2005). The antler consists of a shaft or 'beam', which grows upwards, and 'tines', which branch to make the forked shape. Both the beam and tines elongate with age, and additional tines are added (Lincoln, 1972, 1994; Krauss *et al.*, 2011). The appearance, size and sturdiness of the antlers are important factors in competition and mate attraction. During the rut, antlers are used as weapons in male–male combat to obtain access to females (Lincoln, 1994; Yamauchi & Matsuura, 2009; Ungerfeld & Canabal, 2014; Morina *et al.*, 2018). Before fighting, stags walk laterally to an opponent, during which they observe and evaluate body and antler size (Alvarez, 1995; Jennings & Gammell, 2018). Older deer have larger and heavier antlers, and thus have a greater likelihood of being dominant. Nevertheless, within the antler cycle, older deer tend to cast their antlers earlier than younger stags (Yamauchi & Matsuura, 2009; Bielli *et al.*, 2017), providing an opportunity for younger individuals to take over from non-antlered individuals (Lincoln, 1994).

Growing antlers may have thermoregulatory functions due to the widespread vascular network in the velvet (Stonehouse, 1968).

(3) Reindeer antlers

In Reindeer/caribou both males and females have antlers, although the antlers of females are smaller than those of males (Lincoln & Tyler, 1994; Loe *et al.*, 2019).

(a) Formation

Primitive protuberances of the pedicles of future antlers are formed in the first week after birth in both males and females (Blake, Rowell & Suttie, 1998). Thus in reindeer the initial formation of the pedicle and antler is independent of puberty. Castration, ovariectomy, and the use of anti-androgens do not impair the formation and development of the antlers in male and female reindeer. Nevertheless, sex hormones in intact reindeer, or exogenous sex hormones in castrated or ovariectomized reindeer are essential components in the timing of seasonal alterations in the antler cycle (Lincoln & Tyler, 1992, 1994, 1999; Lincoln, 1994; Bubenik *et al.*, 1997; Blake *et al.*, 1998). Velvet formation is initiated at around the first month after birth and antler development is terminated after 18 and 21 weeks in females and males, respectively. In the yearling, antlers are cast from mid-March to mid-April. In the adult reindeer, casting takes place after autumn in the males and after winter in pregnant and non-pregnant females (Lincoln & Tyler, 1994; Bubenik *et al.*, 1997; Blake *et al.*, 1998; Reimers, Nieminen & Tsegaye, 2013; Loe *et al.*, 2019). Circulating levels of testosterone increase greatly during antler mineralization in males, whereas testosterone levels are negligible in females throughout the antler cycle. In females, oestradiol levels increase dramatically during the peak antler mineralization period. In addition, antler growth is promoted by increases in body

mass and IGF levels in both sexes (Lincoln & Tyler, 1994, 1999; Bubenik *et al.*, 1997; Blake *et al.*, 1998).

Lin *et al.* (2019) demonstrated that *CCND1*, one of the genes that regulate antlerogenesis in Cervidae, has two motifs that act as androgen receptor binding sites in reindeer, while roe deer (*Capreolus capreolus*) have one motif for the same gene. Lin *et al.* (2019) deduced that the formation of female antlers might be attributed to the extra motifs on *CCND1*, which could increase sensitivity to low androgen levels. This may partially explain the early formation of antlers in both males and females, i.e. antlerogenesis prior to sexual maturity. In human infants, small quantities of androgens are synthesized in the adrenal glands (Schiebinger *et al.*, 1981; Ahn *et al.*, 2019) and, if this is also the case in reindeer, traces of adrenal androgens together with any gonadal androgens present may trigger antlerogenesis in young reindeer. The presence of plasma cortisol in young reindeer was reported by Lund-Larsen, Kofstad & Aakvaag (1978), implying that the adrenal glands may function at early ages in this species. Adrenal androgens have been reported to be antlerogenic factors in adult female reindeer (Lincoln & Tyler, 1994).

(b) Function

Reindeer inhabit very high latitudes with extensive snow and ice cover during the cold season (Lincoln, 1994; Bubenik *et al.*, 1997; Loe *et al.*, 2019), making their antlers important for foraging. The males use their antlers primarily as weapons during combat with other males in the autumn, after which they are shed. Females maintain their antlers for longer, and employ them during foraging, and in competition with other females and with antlerless males over food sources in the cold season (Lincoln & Tyler, 1994; Bubenik *et al.*, 1997; Holand *et al.*, 2004; Weckerly, Ricca & Giguère, 2014; Holand & Weladji, 2018). Oestradiol is thought to contribute to the later casting of antlers in female reindeer. Interestingly, exogenous oestradiol administration to male red deer prevents casting of the hard antler (Lincoln, 1994; Lincoln & Tyler, 1999).

Possession of antlers is thought to be important for foraging in pregnant females in the cold season and during the spring when calves are born. The smaller female antlers are less costly to produce, allowing conservation of energy and minerals for pregnancy and calving. They also require less energy to carry, meaning they can be retained for a longer period of time (Lincoln & Tyler, 1994; Reimers *et al.*, 2013; Holand & Weladji, 2018; Loe *et al.*, 2019).

III. HORNS

The family Bovidae possess horns consisting of two parts: an outer hard keratinous sheath and an inner bony core. This section describes the formation, structure and function of these two parts and related tissues.

(1) Formation

In cattle (*Bos taurus*), the primitive horn bud develops during the early months of gestation in the epidermis and dermis of the horn locus (Reese *et al.*, 2007; Wiener *et al.*, 2015). In comparison with other regions of the frontal integument, the epidermis of the horn loci becomes much thicker and develops vacuolated keratinocytes between the second and the sixth month of gestation. From the third or fourth months to the end of gestation, thick mesenchymal fibres (nerve bundles) appear in the dermis of the horn bud that are absent in the surrounding dermis in the frontal area. There is no ossification *in situ* before birth (Wiener *et al.*, 2015; Li *et al.*, 2018). It is thought that horn bud mesenchymal cells arise from epithelial cells *in situ* via epithelial-to-mesenchymal transition regulated by *ZEB2* and *TWIST1* genes (Capitan *et al.*, 2011, 2012; Allais-Bonnet *et al.*, 2013). In yak (*Bos grunniens*), osteoblast-differentiating factors including gap junction alpha 1 protein (GJA1) and fibrillin 2 (FBN2) were found in the integument of the horn bud region (Li *et al.*, 2018). GJA1 and FBN2 participate in skeletal bone formation (Jiang, 2007; Nistala *et al.*, 2010; Tiedemann *et al.*, 2013; Buo & Stains, 2014), although no evidence of ossification in horn loci was observed in yak foetal stages (Li *et al.*, 2018).

In cattle, after birth, a pair of hairy spots appear on the horn buds, followed by the formation of protrusions under the skin above the frontal bone (Fig. 2A, B). Under the influence of the epidermis, dermis and underlying connective tissues, a pair of primitive cores then develop above the frontal area. These connective-tissue-like cores will later form the bony core of the horn. These primitive cores have no adhesion to the underlying frontal bone (Fig. 2B). Thus, initial core bone formation is separate (and probably independent) from development of the frontal bone and its periosteum. The cores develop in tandem with elevation (protrusion) of the frontal bone. At around 2 months of age, the primitive core fuses with the underlying frontal bone in the protruded area (Fig. 2C) (Dove, 1935; Reese *et al.*, 2007; Cattle standards, 2013; AVMA, 2014; Hall, 2015; Nydam & Nydam, 2016; McGeady *et al.*, 2017), i.e. the core passes through the underlying periosteum (or becomes incorporated into the periosteum). Subsequently, the core begins to grow upwards and ossifies, associated with exterior changes in the epidermis. The hairy epidermis becomes keratinized (cornified) to generate a hard integument (Dove, 1935; Goss, 1983; Hall, 2015; McGeady *et al.*, 2017) which is visible and commonly termed 'horn'. Janis & Scott (1987), referring to Dürst (1902a, 1902b, 1926), stated that the core bone ossification takes place in the dermis, and thus is 'intramembranous' and reported that no cartilage formation occurs before or during ossification. At around 6 months of age, the frontal sinus enters the base of the bony core (pneumatization) (Schummer *et al.*, 1976; Habel & Budras, 2003; Reese *et al.*, 2007) and proceeds until 3 or 4 years of age (Moussu & Dollar, 1905). Pneumatization creates a spongy (hollow) structure in the core bone, except for at its tip where it remains non-spongy (Fig. 2D) (Sisson & Grossman, 1955;

Reese *et al.*, 2007; McGeady *et al.*, 2017). Keratinization of the epidermis continues throughout the animal's life and, depending on the species, the horns can take various lengths, sizes, and shapes (Lyon, 1908; Goss, 1983; Janis & Scott, 1987). The keratinized sheath usually is not shed but it may exfoliate [e.g. in oryxes and kobs (O'Gara & Matson, 1975; Yu *et al.*, 2014)]. The age at which development of the bony core is complete is not yet clear.

Some bovid individuals or breeds are 'polled', i.e. they do not develop horns or horn-like protrusions (Capitan *et al.*, 2011, 2012; Schafberg & Swalve, 2015; Duijvesteijn *et al.*, 2018; NYSCHAP, 2018), nor do they develop frontal bone protrusions (Sisson & Grossman, 1955). During foetal stages, polled individuals do not develop thick mesenchymal fibres in the dermis at the presumptive site of the horn bud (Wiener *et al.*, 2015), and the epidermis at this site remains similar to the epidermis of the rest of the scalp (Li *et al.*, 2018).

Genetics or pathological aetiologies can lead to 'scurs', or non-developed horns, instead of true horns above the frontal area (Kyselý, 2010; Capitan *et al.*, 2011; Wiedemar *et al.*, 2014; Duijvesteijn *et al.*, 2018; He *et al.*, 2018). Scurs mostly possess a bony core which is detached from the frontal bone (unfused), making them loose at the base (Dove, 1935; Capitan *et al.*, 2011; Medugorac *et al.*, 2012; Schafberg & Swalve, 2015; He *et al.*, 2018). In addition, the keratinized layer is poorly developed. Contrary to normal core bone formation, the frontal bone is not protruded, and pneumatization does not take place, giving the scur structure a high density (Dove, 1935; Capitan *et al.*, 2011).

There are cases or breeds of bovid which have extra horns that form from a pair of horn sites (Blunn, 1943; Nadri, 2013; He *et al.*, 2016, 2018). These extra horns seem to originate from the ipsilateral main horn site. One such pattern in extant Bovidea occurs in the four-horned antelope (*Tetracerus quadricornis*) in which males have two pairs of horns formed on the frontal bone (Modell, 1969; Leslie & Sharma, 2009; Meghwal, Bhatnagar & Koli, 2018). Their development can be attributed to a division in the core bone's anlagen (primordium) (Janis & Scott, 1987), allowing the horns to arise from four segregated buds. Core bone formation and keratinization of multi-horn structures have not been elucidated to date.

(a) Keratinization and ossification

It is not clear whether keratinization is caused by ossification, or whether they proceed in parallel. Three sources of evidence suggest that they take place in parallel: (i) in cattle with scurs, both the core bone and keratinized epidermis are underdeveloped; (ii) in hornless (polled) individuals, the skin covering the presumptive horn region is similar to the surrounding skin; (iii) hornlessness is due to dominant autosomal genes in cattle (Medugorac *et al.*, 2012; Wiedemar *et al.*, 2014; Götz *et al.*, 2015; Stafuzza *et al.*, 2018). With regard to the latter, the presence or absence of both the keratinized sheath and core bone appear to be under the control of the same genes, thus keratinization and ossification are likely to

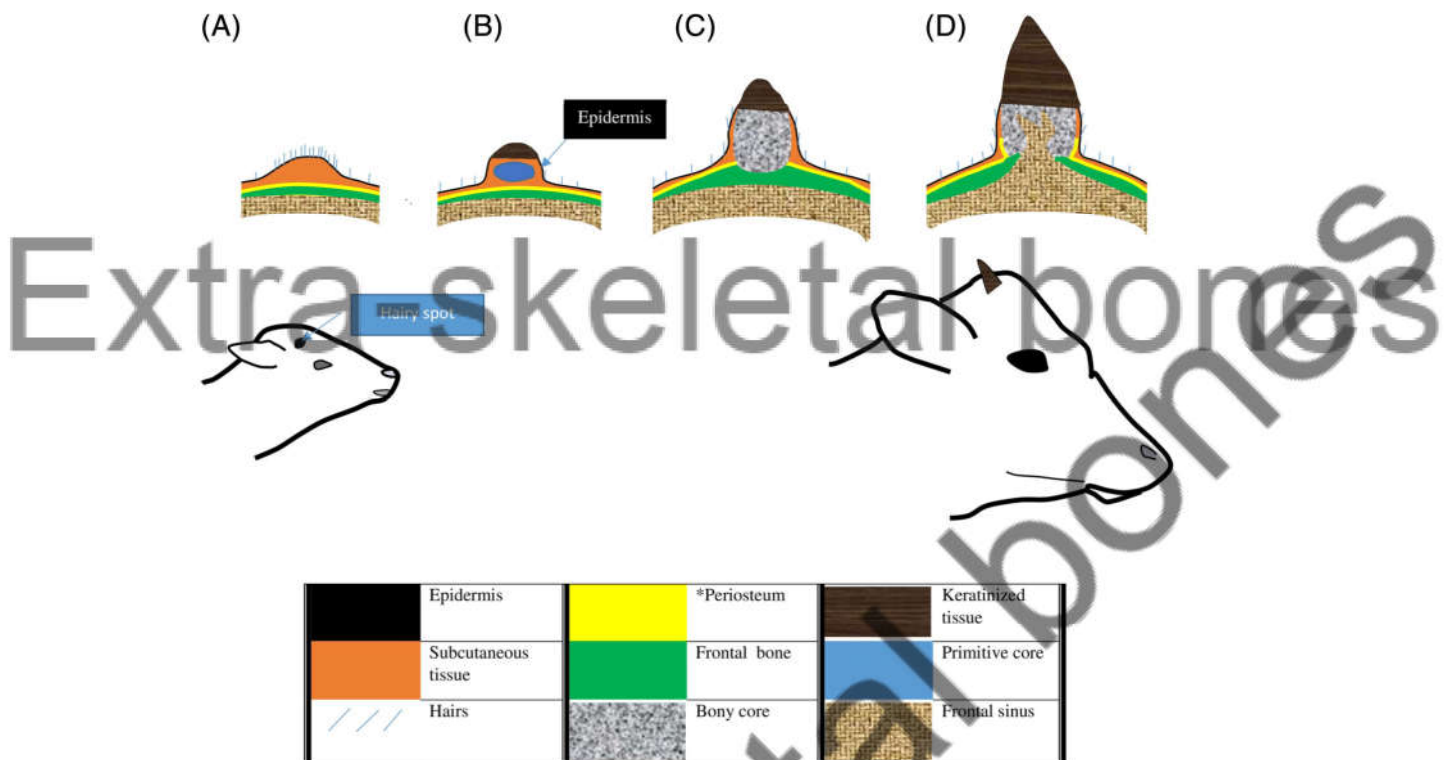


Fig. 2. Lateral view of the skull at the region of the developing horn to show stages in horn development in cattle (*Bos taurus*). (A) In the newborn calf there is no tangible protrusion on the skull, but the site of the future horn site is covered by a pair of hairy spots. Beneath the epidermis, mesenchymal structures and sebaceous glands accumulate. Elevation of the underlying frontal bone begins. (B, C) In the juvenile between 2 and 6 months of age a protrusion is visible and the primitive core develops under the epidermis and above the frontal bone. Keratinization has already begun on the epidermis. The core undergoes ossification and then is fused to the underlying protruding (dome-shaped) frontal bone. (D) From 6 months of age to adulthood, the frontal sinus enters the base of the core and pneumatization proceeds until 3 or 4 years of age. Keratinization continues incrementally on the epidermis. *It is not clear at what stage the periosteum is formed around the core bone. In the adult the core bone is overlaid by the periosteum.

proceed together. The presence or absence of horn formation is not sex dependent in cattle, and both sexes develop horns. Interestingly, in some bovid species only males are horned, and the control of this deserves to be studied further.

(b) Horn generative region

It remains unclear whether the initiation of primitive core bone formation in bovids is governed by the frontal bone and its periosteum or by the integument and subcutaneous tissues. There are two sources of evidence that support the latter. (i) Scurs develop and ossify subcutaneously, while they are detached from the frontal bone and periosteum (Dove, 1935; Capitan *et al.*, 2011; Medugorac *et al.*, 2012; Schafberg & Swalve, 2015; He *et al.*, 2018). (ii) The process of disbudding and dehorning involves removal of the integument and the underlying connective tissues, and can permanently prevent horn growth. This technique is commonly used in very young calves, when only the horn bud is present, but can also be used on horned adults. During disbudding, full-thickness skin on the horn bud is removed. In older individuals, the horn from the base (including both the keratinous sheath and core bone) is cut off, following which a full-

thickness skin about 1 cm from the horn base is excised. Any failure to remove the entire local integument can lead to regrowth of the horn or formation of scurs in both subadults and adults (Quinlan, 1940; Shilkin, 1961; Kersjes, Németh & Rutgers, 1985; Hoffsis, 1995; Hull, 1995; Aubry, 2005; Cattle standards, 2013; AVMA, 2014; Nydam & Nydam, 2016). It is not necessary to manipulate the calvarium surface or damage the bony base of the skull (Quinlan, 1940; AVMA, 2014). Similar procedures for prevention and excision of the horn apply to goats (Hull, 1995; Al-Sobayil, 2007; White, 2004; Hempstead *et al.*, 2018). It is thus clear that the epidermis, dermis and underlying connective tissue play a major role in horn (bony and keratinous tissue) formation. Some workers cite the dermal tissue as the origin of core bone formation of the horn (Capitan *et al.*, 2012; Hall, 2015; Schafberg & Swalve, 2015). The periosteum and frontal bone only have a minor role in the initiation of both core bone formation and keratinization. However, the frontal bone and periosteum in the horn loci do contribute to the development of the bony core *via* frontal bone protrusion, fusion to the core bone, pneumatization, and further core bone growth.

(2) Structure

Due to its tough yet flexible properties, horn has a shock-resistant structure (Maity & Tekalur, 2011; Drake *et al.*, 2016; Zhang *et al.*, 2018b). In bighorn sheep (*Ovis canadensis*), horns can withstand a 3400 N force during male–male combat (Johnson *et al.*, 2017) and in cattle the horn can withstand 7600 N in compression tests (Li, Zhao & Feng, 2011). Such mechanical stresses could be lethal in other animals; for example, in humans a strong punch to the head can inflict lethal injuries (Atha *et al.*, 1985; Walilko, Viano & Bir, 2005). These mechanical properties of horn are due partly to the keratinized sheath and partly to the bony core (Li *et al.*, 2011; Wang *et al.*, 2016a; Cappelli *et al.*, 2017; Johnson *et al.*, 2017). Horn absorbs and transfers the inflicted force from the keratinous layers first to a layer of fluid between the keratinized part and the core bone (Zhu, Zhang & Zhao, 2016), then to the core bone and frontal sinus, and finally to the neck and shoulder bones and muscles (Farke, 2010b; Maity & Tekalur, 2011).

(a) The integument

From the exterior to the interior, the horn consists of a keratinized epidermis, dermis, and core bone. The epidermis includes three parts, the stratum basale, st. spinosum, and st. corneum, the latter of which forms the keratinized layer (Bacha & Bacha, 2012). The keratin sheath in cattle is seven times tougher than the bony core (Yu *et al.*, 2014). The keratinized layer, which is supplied by the lympho-vascular system and is well innervated (George, 1955; Habel & Budras, 2003; Reese *et al.*, 2007), grows incrementally throughout life (Lyon, 1908; Goss, 1983), at a rate of about 22 cm per year in bighorn sheep (Goss, 1983).

The horns of the male are generally larger than females. Depending on species and fighting style, horns (both the keratinous sheath and bony core) can have different shapes (e.g. straight, curved, spiral, etc.), microstructure, and length (Modell, 1969; Schummer *et al.*, 1976; Gentry, 1992; Lundrigan, 1996; Calamari & Fossum, 2018; Zhang *et al.*, 2018b). They range in length from about 3 cm in male royal antelope (*Neotragus pygmaeus*) (Bro-Jørgensen, 2007) to about 150 cm in male water buffalo (*Bubalus bubalis*) (Surakamhang & Sangsuebun, 2015) and 122 cm in sable antelope (*Hippotragus niger*) (Bro-Jørgensen, 2007).

In cattle, the dermal papillae of the dermis cover the core bone periosteum. The dermis at the base of the horn merges with the frontal bone periosteum, and continues with it onto the frontals. The horn dermal tissue is highly vascularized and innervated, but is glandless (Moussu & Dollar, 1905; Krölling & Grau, 1960; Sisson, Grossman & Getty, 1975; Schummer *et al.*, 1976; Anon, 2002b; Habel & Budras, 2003; Reese *et al.*, 2007).

In sheep, a vascular connective tissue layer exists between the bony core and the keratinized layer of the horn (George, 1955). Using electron microscopy, Zhu *et al.* (2016, p. 672) described the periosteum as ‘a layer of fibrous coat composed

of compact connective tissue’ on the bony core. This periosteum overlays the core bone surface, which is ridged and filled with fluid (Zhu *et al.*, 2016).

(b) The core bone

The core bone is highly vascularized by branches of the coronal artery (George, 1955; Taylor, 1966; Hoefs, 2000; Habel & Budras, 2003; Reese *et al.*, 2007). The external surface of the core bone in cattle is rough, ridged, and foraminated (Sisson & Grossman, 1955). A ridged pattern on the core bone surface has been reported in other bovids too (Solounias, 2007a). The internal part of the core bone in the middle cavity is spongy, resulting from pneumatization (Yu *et al.*, 2014; Zhu *et al.*, 2016), and contains some marrow (Li *et al.*, 2011). The sponginess of cattle core bone is 66% at the distal end of the horn and 50% at the proximal end. This gradient in porosity gives higher mechanical resistance to the base than the tip of the horn. Microstructurally, the core bone is primarily composed of trabecular bone (Li *et al.*, 2011; Maity & Tekalur, 2011; Yu *et al.*, 2014; Drake *et al.*, 2016; Zhu *et al.*, 2016), with a density of 0.9 g/cm³ in cattle horn (Yu *et al.*, 2014). The core bone outer surface layer is composed of cortical bone. The trabecular bone and the porous architecture of the core bone allow dissipation of forces inflicted during ramming (Maity & Tekalur, 2011; Drake *et al.*, 2016; Zhu *et al.*, 2016; Cappelli *et al.*, 2017).

In Bovidae, the bony core is usually connected directly to the frontal bone. However, in some species such as the dorcas gazelle (*Gazella dorcas*) (Solounias, 2007a) and the hartebeest (*Alcelaphus buselaphus*) (Vrba, 1979) there is a stiff fused pedicle located between the base of the core bone and the frontal bone.

(c) Pneumatization

Ingrowth of the frontal sinus into the base and body of the bony core (pneumatization) takes place in some bovid species but not in others: the frontal sinus enters the core bone in the Tibetan antelope (*Pantholops hodgsonii*), springbok (*Antidorcas marsupialis*), and cattle, whereas sinus extension into the core bone is very limited or not present in *Aepyceros* spp., Cephelophini, and all taxa in Alcelaphinae. This lack of pneumatization creates a dense and heavy structure in the core bone (Farke, 2007, 2010b; Solounias, 2007a).

Pneumatized bone is also found in the skeleton of birds, where it functions to reduce body weight during flight. Interestingly, in diving birds the skeleton is not pneumatized (Cubo & Casinos, 2000; Apostolaki, Rayfield & Barrett, 2015; Lambertz, Bertozzo & Sander, 2018). This seems consistent with an ‘opportunistic pneumatization’ hypothesis for the bovine skull that sinuses remove bone that is unnecessary for structural support of the skull (Farke, 2008a,b, 2010a,b). As discussed above, during core bone formation, the frontal bone protrudes at the site of the horn bud, creating an enlarged underlying sinus. Geist (1966) noted that pneumatized bone occurs in the skulls of species (even non-horned

species) that use their head in combats with rivals. In apes (such as gorillas), in which headbutting is not common, the males have an enlarged sagittal crest (Ashton & Zuckerman, 1956; Cave, 1961; O'Higgins *et al.*, 1990; Balolia, Soligo & Wood, 2017) and enlarged underlying sinuses (Cave, 1961; Blaney, 1986; Preuschoft, Witte & Witzel, 2002). It has been demonstrated that the sagittal crest and enlarged sinus, in addition to strengthening the skull and reducing skull weight (Blaney, 1986; Preuschoft *et al.*, 2002), function as signals of visual dominance and confer a higher mating success in male apes (Balolia *et al.*, 2017; Gleeson, 2018; Wright *et al.*, 2019). Clearly, skull bony protrusions such as horns (with or without pneumatization), the sagittal crest and their underlying enlarged sinuses have both mechanical and visual functions.

(3) Function

Horns are used primarily in male–male combat and social dominance, but also function in defence against predators and in foraging (Bro-Jørgensen, 2007; Yu *et al.*, 2014; Knierim, Irrgang & Roth, 2015; Schafberg & Swalve, 2015; Nasoori *et al.*, 2016).

In bovids, males tend to possess horns, while females do not (Bro-Jørgensen, 2007; Solounias, 2007a; Leslie & Sharma, 2009): e.g. in Neotragini, Boselaphini (Kiltie, 1985), Tragelaphini, *Tragelaphus* spp. (Wilson, 1965; Kiltie, 1985; Bro-Jørgensen, 2007; Leslie & Sharma, 2009) and the saiga antelope (*Antilopini tatarica*) (Sokolov, 1974; Kiltie, 1985; Bro-Jørgensen, 2007) females are hornless. In genera in which females are horned, their horns are usually smaller than those of males (Modell, 1969; Schummer *et al.*, 1976; Kiltie, 1985).

It has been proposed that females evolved horns in response to high levels of competition for resources (such as food or territory). Female horns have defensive functions against predators, to protect themselves and their young. Visual effects of female horns, through andromimicry, may also deter predators (Roberts, 1996; Clutton-Brock, 2009; Stankowich & Caro, 2009; Knierim *et al.*, 2015). In species with horned females, male horns tend not to be elaborate, unlike those of males in species with hornless females. This may reflect a trade-off involving the ability of females to use their horns offensively and in defence (Bro-Jørgensen, 2007). Horns can also affect thermoregulation (Solounias, 2007a; Parés Casanova & Kucherova, 2014). A study on different species of wild sheep revealed that the surface area of the core bone is smaller in species from colder areas (e.g. the arctic and Siberia) than warm areas. This was attributed to heat loss *via* the bony core vascular network (Taylor, 1966; Hoefs, 2000).

IV. PRONGHORNS

Pronghorns (*Antilocaprida americana*) are the only extant member of Antilocapridae (Chorn, Frase & Frailey, 1988; Davis,

2007; Hoffman, Genoways & Jones, 2011). Their horns have peculiar features that make them distinctive from other horn/hornlike structures in extant mammals. (i) They have a bony core with a mediolaterally compressed (blade-like) shape (Lyon, 1908; Davis, 2007), unlike the conical (oval or round in cross section) shape seen in the majority of bovids (Solounias, 2007a), or branched structures of cervids. (ii) Although the bony core is not bifurcated, the keratinized sheath is branched to form a characteristic hook and prong (Lyon, 1908; O'Gara & Matson, 1975; Hall, 2015). This contrasts with that of Bovidae where the keratinous sheath follows the unbranched pattern of the bony core (Solounias, 2007b). (iii) The keratinized sheath is cast every year, and re-keratinized afterwards (Lyon, 1908; Skinner, 1922), whereas bovid horns are either not cast or if they are this takes place irregularly (exfoliation) (Lyon, 1908; O'Gara & Matson, 1975; Goss, 1983; Solounias, 2007a). Re-keratinization similar to that of pronghorns has not been reported in bovids. (iv) The size of the horns does not change after 2 or 3 years of age (Mitchell & Maher, 2001, 2006; Brown & Mitchell, 2005). Conversely, in the majority of bovids continuing keratinization allows the horn to increase in size throughout the animal's life (Lyon, 1908; Goss, 1983). (v) The whole sheath is cast together (Skinner, 1922; O'Gara & Matson, 1975) similar to removing a glove. This differs from the typical gradual lysis of the keratinized epidermis in most mammals. Complete shedding of the epidermis has been reported in whales (Spearman, 1966; Coghlan, 2016) and seals moult annually (Carrick, Csordas & Ingham, 1962; Champagne *et al.*, 2015; Ling, 2018).

(1) Formation

Pronghorns are born hornless and gradually develop their horns during the first few months after birth. In the first winter they shed the horn sheath. The prong, which is non-osseous and originates in the keratinous sheath, is formed during the second year of life. The horns reach their largest size (about 30 cm length and 15 cm circumference) at around 2–3 years of age (Lyon, 1908; Brown & Mitchell, 2005; Brown, Gonzalez-Suarez & Hankda, 2006).

(2) Structure

From the exterior to interior, the horn is composed of epidermis, dermis and core bone (O'Gara & Matson, 1975), which is located in the frontal bone (Lyon, 1908; Skinner, 1922). Janis & Scott (1987) stated that the core bone arises from dermal tissues, whereas Solounias (1988a) believed that it forms from a direct outgrowth (apophysis) from the frontal bone. The core is pneumatized by an underlying sinus which encroaches into the supra-orbital area (Janis & Scott, 1987). However, another study demonstrated a lack of pneumatization in pronghorn horns (Snively & Theodor, 2011). This species has a very reduced or absent frontal sinus (Farke, 2010b; Snively & Theodor, 2011). The epidermis consists of a stratum germinativum (basale), st. granulosum, and

st. corneum. The epidermis is keratinized when in sheath and covered by hairs after the sheath is cast (Skinner, 1922; O’Gara & Matson, 1975). The hairy (non-keratinized) epidermis was termed ‘thick velvety membrane’ or ‘keratovelvet’ by Skinner (1922) and Bubenik & Bubenik (1990), respectively.

Casting takes place only in the sheath, while the bony core is permanent and remains unchanged. Casting proceeds by detachment of the underlying epidermis; a new keratinized bump grows on the epidermis at the tip of the core bone causing detachment of the existing sheath (Fig. 3A). This is accompanied by growth of hairs on the epidermis on the basal part of the horn. The old sheath is then shed (Fig. 3B) and new keratinization expands both longitudinally and radially, to form the hook and prong (Fig. 3C, D) (Lyon, 1908; Skinner, 1922; O’Gara, Moy & Bear, 1971; O’Gara & Matson, 1975). The hairs are incorporated into the cornified compartment of the sheath (Lyon, 1908; Skinner, 1922; O’Gara & Matson, 1975; Zhang *et al.*, 2018b), unlike in cattle where the epidermis becomes devoid of hairs during keratinization (Dove, 1935; Goss, 1983; Zhang *et al.*, 2018b).

Female pronghorn have smaller horns than males, and some females even lack horns. Horned females have a sheath-casting cycle which differs slightly from that of males in mechanism and timing; casting is rather irregular and results in multi-sheath formation. This has been attributed

to the smaller size of the female horn which cannot press the older sheath upward with sufficient force to cast it off. Similar results were reported for a castrated male pronghorn which showed an irregular mechanism and timing that led to under-developed and multi-layered sheath formation (Lyon, 1908; O’Gara, 1969; O’Gara *et al.*, 1971; Chorn *et al.*, 1988; Davis, 2007; Rico-Guevara & Hurme, 2019).

(3) Function

Pronghorns use their horns in: (i) social communication in which they make horn-to-horn contact with the head lowered; (ii) fighting and defence, where males use their horns in combat against rivals by striking and locking their horns, then pushing the rival off balance, or using them to stab the head or neck (Bromley, 1969; Kitchen, 1974; Zhang *et al.*, 2018b). Pronghorn males are territorial, and guard females (Rico-Guevara & Hurme, 2019).

The sheath reaches maximum hardness near the time of rut (mid-September in the USA) which is after maximum testicular development. Casting of the sheath takes place after rut in autumn or early winter, followed by re-keratinization. The sheath is fully formed by early summer. Casting occurs earlier in older individuals (Lyon, 1908; O’Gara *et al.*, 1971).

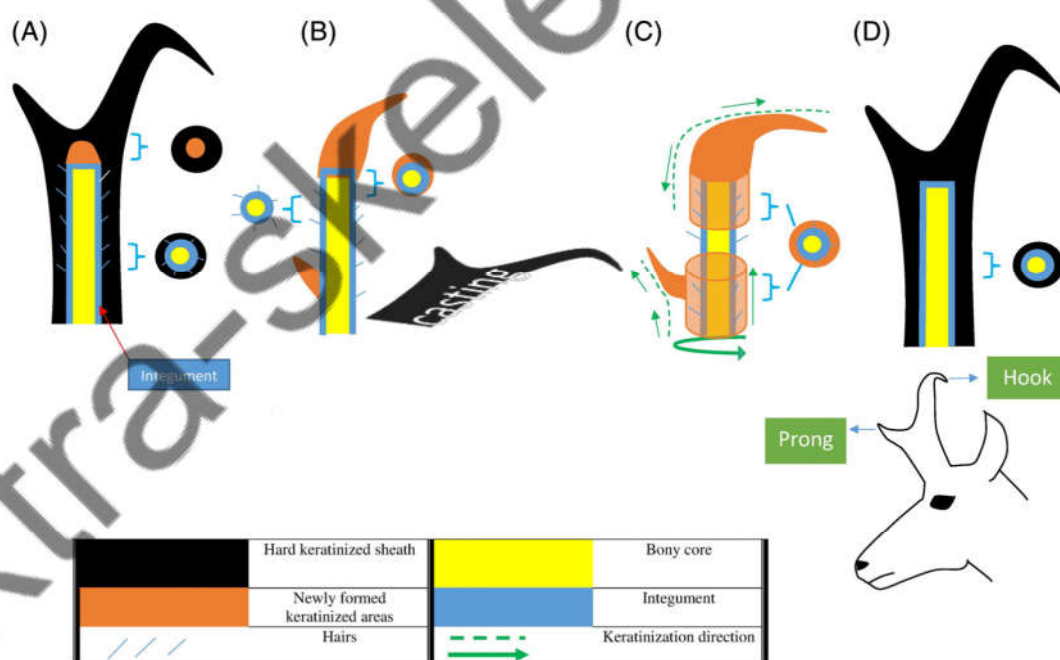


Fig. 3. Casting and keratinization of the sheath in adult pronghorn (*Antilocapra americana*). Lateral and transverse views. (A) Before casting of the old sheath, a new keratinized layer forms on the epidermis at the top of the core bone. On the lower parts, hairs are growing while the (old) keratinized sheath is still present. (B) The entire sheath is cast (shed) followed by keratinization leading to formation of the primitive hook and prong. The hairy integument on the bony core is apparent. (C) Expansion of the keratinized sheath takes place in three directions: from the top down, from the bottom up, and radially. Hairs are incorporated into the keratinized sheath. (D) The new keratinized sheath is formed and hardened over the bony core.

V. OSSICONES

(1) The giraffe

(a) Formation

In the giraffe (*Giraffa camelopardalis*), a pair of primitive cores begin to form under the integument above the parietal bone from around day 306 of gestation. After birth, the core beneath the integument develops into a connective tissue capsule. The ventral side (base) of this tissue is perforated and is juxtaposed to a highly vascularized arterial mat (which also contains nerve bundles) located on the parietal bone (Fig. 4A). The vessels in the arterial mat, which are supplied by the cornual artery, access the core through the perforated surface of the surrounding capsule. At around 6 months of age, the vascular plexus disappears and in adulthood the bony core is nourished by extended vessels from the cornual artery (Lankester, 1907b; Spinage, 1968; Ganey, Ogden & Olsen, 1990; Bercovitch *et al.*, 2004; O'Brien *et al.*, 2016).

From birth onwards, the encapsulated core gradually enlarges and expands onto the frontal bone. In a 10-month-old male, the core completely abutted the parietal

bone and encroached slightly onto the frontal bone (Lankester, 1907b; Spinage, 1968; Ganey *et al.*, 1990). At the same time, the frontal sinus grows and expands in different directions under the calvarial bone (Fig. 4B) (Badlangana, Adams & Manger, 2011). Sinus expansion has two main effects: (i) the frontal sinus advances caudally under the parietal bone; (ii) it produces a bony protrusion in the parietal area which later will form the base of the main (lateral) ossicones. A similar bony protrusion is formed on the nasal bone under the median ossicones (Badlangana *et al.*, 2011). The encapsulated cores are not fused to the underlying bone until about 4 years of age in males and 7 years in females (Fig. 4B) (Spinage, 1968).

During ossicone development, the perforated basal surface favours the invasion of the underlying connective tissue which creates the anchorage to the underlying bone (Spinage, 1968; Ganey *et al.*, 1990). Some workers reported the presence of cartilaginous tissue under the ossicones (Spinage, 1968, 1993; Solounias, 1988b; Geraads, 1991). However, histological analyses have clearly demonstrated the presence of dense connective tissue rather than cartilage under the ossicone core (Ganey *et al.*, 1990). The basal

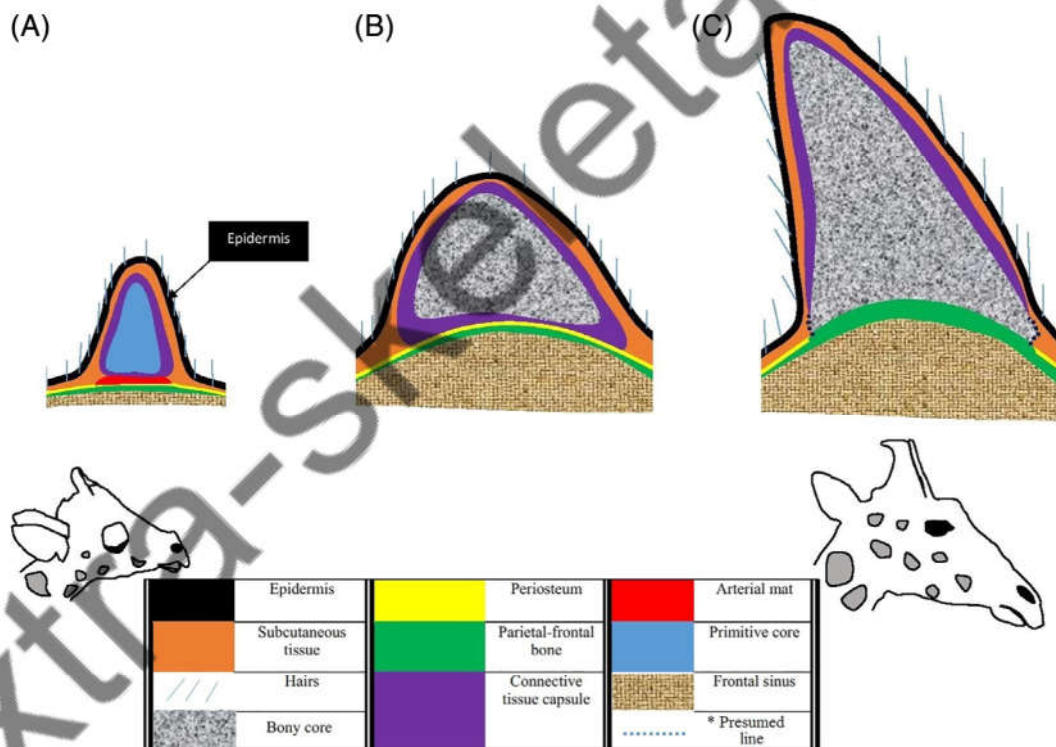


Fig. 4. Lateral view of the skull bone in the region of the ossicone to show ossicone development in the giraffe (*Giraffa camelopardalis*). (A) Giraffes are born with observable cranial appendages covered with hair. The primitive core, which is not yet ossified, is encapsulated in connective tissue and overlies the arterial mat on the parietal bone. (B) In juveniles [from about 6 months (or before the fusion of the base of ossicone to the underlying bone) to 4 or 7 years of age in males and females, respectively] the core grows and undergoes ossification while surrounded by the connective tissue capsule and encroaches cranially onto the frontal bone. The frontal sinus advances underneath to form a domed base. (C) In the adult the core, which is large, is fused to the parietal and frontal bones on its ventral side. After fusion, the core continues to develop slightly during the animal's life. *There are few data regarding the function of the periosteum in ossicone formation. Here it is presumed that the frontal periosteum adheres to the connective tissue capsule.

connective tissue disappears by the time the core's base is fused to the parietal and frontal bone (Fig. 4C) (Janis & Scott, 1987; Ganey *et al.*, 1990). Illustrations in Badlangana *et al.* (2011) placed the frontal sinus under the ossicones. By contrast, Lankester (1907b) reported that both the frontal and parietal sinuses are connected to the ossicone base.

Ossification of the core is largely complete inside the capsule by the time of fusion and is similar to the pattern of intramembranous ossification. In the middle part of the core, however, there remain some cartilaginous patches which are ossified later (Ganey *et al.*, 1990). The connective tissue around the ossicones remains even after fusion, and continues ossification in both longitudinal and radial directions, although at a much reduced rate (Fig. 4C) (Ganey *et al.*, 1990). In adult giraffes, the ossicones undergo an extra secondary ossification accomplished by the core bone cells and/or by the dermal tissues (Spinage, 1968; Solounias, 2007b).

The development of the median (unpaired) ossicone on the naso-frontal area follows a similar developmental pathway (Spinage, 1968, 1993; Solounias, 2007b; Van Sittert, 2016).

(b) Structure and function

From the exterior to interior, the ossicone is composed of a hairy epidermis, dermis (mainly connective tissue) and core bone (Modell, 1969; Ganey *et al.*, 1990; Solounias, 2007b) all of which are permanent (Hall, 2015). The tip of the ossicone is almost devoid of hair, where the skin is exposed (Fig. S4). The skin at the tip of the ossicone is periodically sloughed away (Dimond & Montagna, 1976).

The surface of the core bone is rough and perforated, facilitating blood supply to the body of the core. The integument, which is highly vascularized, together with the core bone and skull sinuses play a role in thermoregulation. In this respect, the nerves of the ossicones receive thermal cues which are followed by vascular reactions and activation of sweat glands in the integument (Spinage, 1968; Ganey *et al.*, 1990; Danowitz, Barry & Solounias, 2017).

Both male and female giraffes have ossicones, but those in males are heavier (Mitchell *et al.*, 2013) and larger than in females (Owen, 1839; Solounias, 2007b). In males, the average length and circumference of ossicones are 18 cm and 22 cm, respectively (Spinage, 1968). Other ossicones are also present on the skull: lateral (main or parietal), median, occipital, zygous and orbital ossicones. All of these protrusions are strengthened by secondary ossification, most prominently in males which use their skull and its bony appendages during fights. Male–male combat usually consists of clubbing and neck-to-neck clashes. This fighting style differs from the ramming used by bovids in which forces are transferred to other parts of the body (see Section III.3). By contrast, females, which mainly use kicking in combat, do not possess considerable secondary ossification (Spinage, 1968; Solounias, 2007b; Hall, 2015; Williams, 2016).

(2) The okapi

(a) Formation

Only male okapi (*Okapia johnstoni*) have ossicones. The core is formed on the frontal bone and similarly to the giraffe it develops into a capsule of connective tissue under the integument of the head (Lankester, 1907b). The frontal sinus in okapi also enlarges under the frontal bone and advances beneath the base of the ossicones (Badlangana *et al.*, 2011). The ossicones grow with age and when the animal's body reaches its mature size, the tip of the bony core is visible protruding through the integument and remains skinless (Lankester, 1907a). Secondary ossification occurs in the ossicone and some areas of the skull (Hou *et al.*, 2014). Median and other ossicones have not been reported in the okapi.

(b) Structure and function

From exterior to interior, the ossicone is composed of the epidermis, dermis, and core bone similar to giraffe ossicones. Unlike the giraffe, the core bone is skinless at the tip (Fig. S5), which undergoes casting (Lankester, 1907a; Solounias, 2007b; Hou *et al.*, 2014). The core bone has a rough surface and is perforated at the base (Lankester, 1907a) which probably facilitates blood supply and attachment to the underlying bone. The distal core has a collar-like groove which separates the covered (skinned) part from the bare tip of the core (Solounias, 2007b).

A skinless (bare) bone is reminiscent of velvetless antlers, however, the mechanism by which the tip of the okapi ossicone becomes exposed has not been described and velvet does not seem to be present in the okapi. One possibility is that the tip of the ossicone protrudes through the skin (Fig. S5). Such a phenomenon is known in other mammals, for example in the babirusa (*Babirusa* spp.) and narwhal (*Monodon monoceros*) the upper canine teeth penetrate the facial skin and grow outwards (Nweeia *et al.*, 2012, 2014; Macdonald, Leus & Hoare, 2016; Macdonald, 2017, 2018).

The tip of the ossicone is a very dense ossified structure containing crevices. Due to bone resorption the ossicone tip is prone to be cast and is considered 'dead' (Lankester, 1907a; Solounias, 2007b; Hou *et al.*, 2014). The concept of a dead, yet functional bone is similar to antlers, which can be seen as 'dead' tissue due to the absence of a blood supply after velvet shedding (Landete-Castillejos *et al.*, 2019). A similar concept of 'dying bone' has been proposed for the vertebral bone of the sperm whale (*Physeter microcephalus*), in which the extent of bone remodelling has been greatly reduced, presumably as an adaptation for swimming at great depths (Rolvien *et al.*, 2017). Further studies on these structures and how they differ from the normal skeleton could broaden our understanding about bone physiology.

The groove between the covered and bare tip on the okapi's ossicone is a distinctive feature among ungulate cranial appendages. Janis & Scott (1987) suggested that the bare tip is an epiphyseal extension of the skinned ossicone, perhaps reminiscent of the connection between the cervid antler

and pedicle. Nonetheless, the connection of the antler is homogenous, and there are no grooves at its junction with the pedicle (Goss & Powel, 1985; Kierdorf *et al.*, 1995; Li & Suttie, 2001). In cattle, stressors such as pregnancy can lead to the formation of fissures or grooves in the horn (McGeady *et al.*, 2017). However, such grooves are a pathological condition mainly involving the keratinized sheath and seem to be completely different from the naturally occurring groove on the okapi bony core.

Okapi ossicones are used in male–male combat involving neck-to-neck clashing, and in guarding females (Danowitz & Solounias, 2015; Rico-Guevara & Hurme, 2019). Despite not having ossicones (Solounias, 2007b), in females the frontal bone is bulged (like that of males) at the presumptive ossicone site (Lankester, 1907b).

VI. ARMADILLO OSTEODERM

In the order Cingulata, the family Dasypodidae has about 21 species of armadillos which possess armour mainly on three parts of the body: (a) the head; (b) dorsal and lateral trunk (carapace); and (c) the whole tail [with the exception of naked-tailed armadillos (*Cabassous* spp.)]. The carapace is divided into pectoral (scapular), banded, and pelvic shields. The armour of the armadillo has two main components: (a) an upper part (visible) formed by keratinized integument (cornified scales); (b) the osteoderm, which is covered by the integument. The osteoderm is structured to form multiple bony tiles in the cephalic shield, carapace (Fig. 5), and caudal sheath (Hill, 2006; Vickaryous & Hall, 2006; Vickaryous & Sire, 2009; Abba & Superina, 2010; Krmpotic *et al.*, 2012; Carlini, Soibelzon & Glaz, 2016).

(1) Formation

In the nine-banded armadillo (*Dasypus novemcinctus*) (the best studied species) during the foetal stage, and prior to the time of osteoderm formation, the epidermis and dermis in the presumptive osteoderm loci are well developed. The scales develop from the epidermis. The dermis has two distinct layers: an upper papillary layer and a lower reticular layer. Hair follicles and sebaceous glands are present in the dermis (Cooper, 1930; Vickaryous & Hall, 2006).

In the late foetal stage, when the body length is about 95–98 mm, the first signs of bone formation are visible in the dermis in the mid-cranial region of the presumptive carapace (Wilson, 1914; Cooper, 1930). The epidermis becomes thicker due to cornification provided by the stratum granulosum (Wilson, 1914; Cooper, 1930). When foetus length is about 120 mm, the osteoderm of the carapace has reached a thickness of about 150 μm and cornification continues to thicken the epidermis (scales). Ossification in the upper layer of the dermis incorporates hair follicles such that they become embedded in the osteoderm (Cooper, 1930).

By the time of birth, osteoderms have been partially formed in all shields. These gradually become fully ossified following birth (Vickaryous & Hall, 2006). In general, ossification proceeds from the cranial to caudal regions of the body, and in medial to lateral directions in the carapace compartments (pectoral, banded, and pelvic shields) and the tail, whereas in the head ossification proceeds from the frontoparietal side towards the nose (Wilson, 1914; Cooper, 1930; Vickaryous & Sire, 2009). Timing of ossification is not synchronous among the different shields (Vickaryous & Sire, 2009; Hautier, Oliver & Pierce, 2018). Before and after birth osteoderm develops in the papillary layer of the dermis where primordial (osteoprogenitor) cells reside. Small blood vessels from the hypodermis vascularize this area. Mineralization in the dermis is associated with trapping the osteoblasts and producing osteocytes. A layer of connective tissue, containing numerous cells, surrounds the mineralized zone, and later creates the periosteum (Vickaryous & Hall, 2006; Krmpotic *et al.*, 2014, 2015). During maturation, primary and secondary osteons are formed in the fibrolamellar matrix of the osteoderm core. Secondary ossification occurs on the existing osteoderm, forming a compact lamellar bone along its dorsal and ventral surfaces. Adult specimens have distinct Sharpey fibres that anchor the osteoderm to the dermis and form joints between adjacent osteoderms. Neurovascular bundles penetrate beneath all osteoderm tiles in all shields, providing a neurovascular network in the medulla of the osteoderm (Hill, 2006; Vickaryous & Hall, 2006; Krmpotic *et al.*, 2015).

Reports on 0–2 day old neonates of the southern long-nosed armadillo (*Dasypus hybridus*) show strong similarities with the above descriptions with regard to osteoderm development. Again there are distinct upper and lower layers in the dermis, accumulated primordial cells are surrounded by a (primitive) periosteum in the upper layer of the dermis, and cornified scales are present in the epidermis. By contrast, in neonates of another species (*ChaetophRACTUS vellerosus*) there are no distinct dermal layers, osteoderm primordia in the dermis, nor cornified scales in the epidermis. However, by the time they reach adulthood, *C. vellerosus* individuals have developed similar osteoderm and epidermal cornified scales, and finally possess a full armour similar to that of *D. hybridus* (Krmpotic *et al.*, 2012, 2014, 2015). The absence of osteoderm primordia raises the question of how ossification is initiated in *C. vellerosus* and may indicate a different mechanism for osteoblast recruitment. A recent study on the American alligator (*Alligator mississippiensis*) showed that endothelial cells of blood vessels at sites of ossification can re-differentiate into osteoblasts, thereby promoting *in situ* ossification (Dubansky & Dubansky, 2018). Given that the dermis is the common origin of osteoderms in alligators and armadillos (Vickaryous & Sire, 2009) it is possible that endothelial cells are also involved in the generation of osteoprogenitor cells in the armadillo, especially in *C. vellerosus*.

In armadillos, osteoderm formation takes place after the development of the skeletal system (Cooper, 1930; Vickaryous & Hall, 2006; Hautier *et al.*, 2011, 2018; Krmpotic

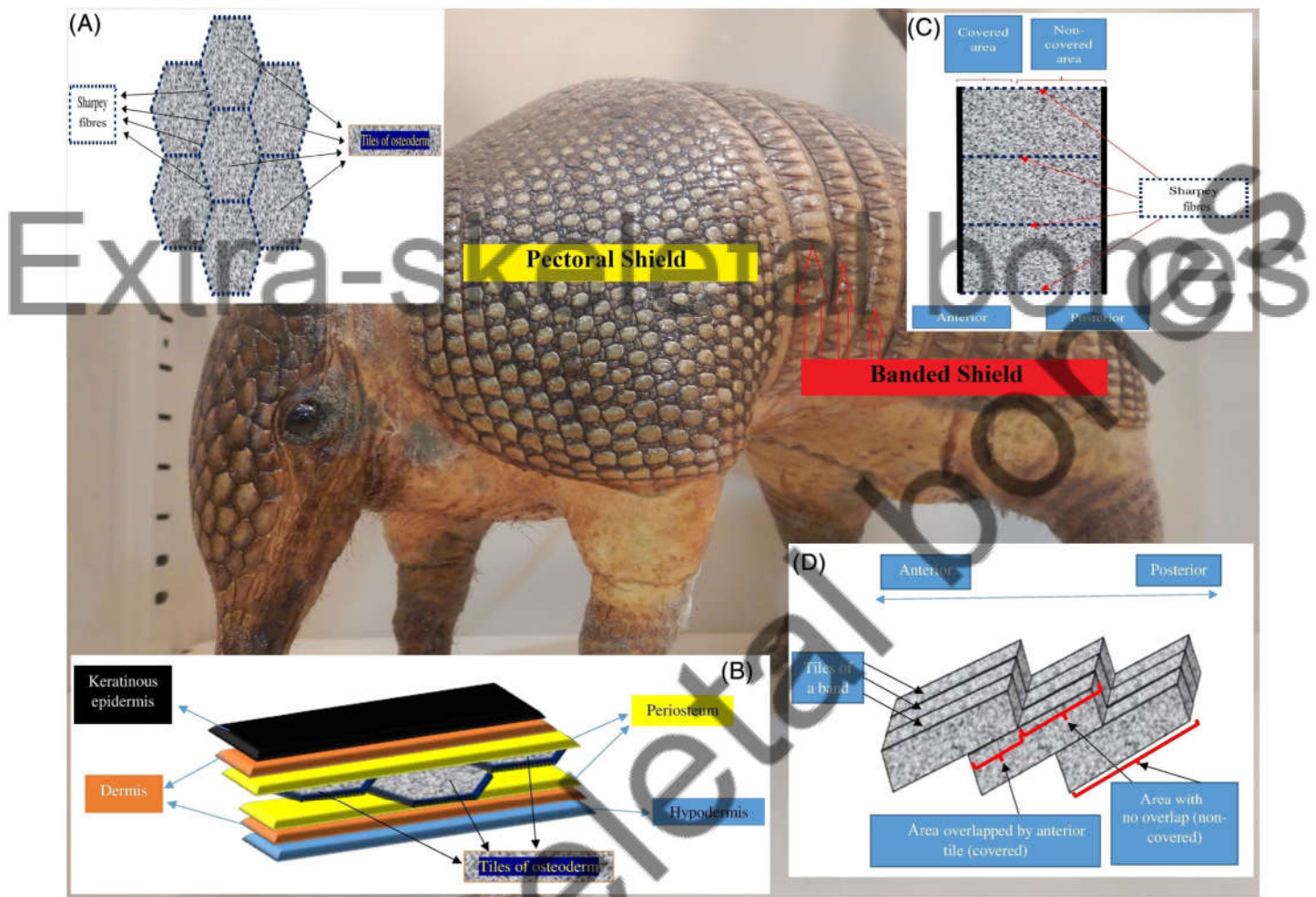


Fig. 5. Armour of the nine-banded armadillo (*Dasypus novemcinctus*). (A) Dorsal view of a few tiles of the pectoral osteoderm. The tiles are connected by Sharpey fibres. The overlying tissues are not shown. (B) Tissues surrounding the osteoderm tiles, shown for three tiles in the pectoral shield. The surrounding tissues are separated for clarity. Tiles are covered by the periosteum and are anchored to the dermis and adjacent tiles by Sharpey fibres. (C) Dorsal view of three tiles of the banded shield. The overlying tissues are not shown. Tiles in a band are connected laterally by Sharpey fibres. Red arrows show the first three bands. (D) Dorso-lateral view of the banded shield. Three tiles are shown in consecutive bands that imbricate with more posterior tiles. The surrounding tissues (epidermis, dermis, periosteum and hypodermis) are similar to those in B, except in the area of tile overlap, where tiles are in contact with the next anterior tile through the periosteum and Sharpey fibres.

et al., 2012) and is accomplished without the involvement of cartilage. It is thus intramembranous ossification (Vickaryous & Sire, 2009; Krmpotic *et al.*, 2012), although Hill (2006) considered it metaplastic bone formation.

(2) Structure

The armour of armadillos consists of head, pectoral, banded, pelvic and tail shields. All of these shields are composed of (from exterior to interior): (i) cornified scales (the epidermis); (ii) thin dermis; (iii) bony osteoderm tiles that represent the largest component of the dermis; and (iv) the underlying hypodermis (Fig. 5B). Each shield comprises multiple linked bony tiles. The majority of these tiles are polygonal (usually

hexagonal) in shape (Fig. 5A) (Hill, 2006; Vickaryous & Hall, 2006; Chen *et al.*, 2011; Chintapalli *et al.*, 2014; Krmpotic *et al.*, 2015).

(a) Osteoderm

The dorsal surface of the osteoderm tiles is ornamented with grooves and foramina from which hairs, vessels, nerves, and ducts of sweat and sebaceous glands project into the epidermis (Chen *et al.*, 2011; Frontini & Vecchi, 2014; Krmpotic *et al.*, 2015). By contrast, the ventral surface of the tiles is rather smooth and is penetrated by foramina containing neurovascular bundles (Vickaryous & Hall, 2006; Krmpotic *et al.*, 2009, 2015). Whereas the dorsal and ventral sides of the tile

are composed of compact lamellar bone, the medulla of the tile is a porous bony cavity containing sweat glands, sebaceous glands, hair follicles, bone marrow, and neurovascular bundles (Vickaryous & Hall, 2006; Krmpotic *et al.*, 2009, 2015; Chen *et al.*, 2014). These medullary components, except the bone marrow, extend towards the dorsal surface *via* the surface foramina. At their lateral margins, the tiles are interconnected by Sharpey fibres (Fig. 5A) (Krmpotic *et al.*, 2009, 2015; Chen *et al.*, 2014). These structures function as tiny joints that allow flexion and extension of the armour during body movements (Chen *et al.*, 2011; Chen *et al.*, 2014; Chintapalli *et al.*, 2014). Sharpey fibres are also present on the dorsal and ventral surfaces and anchor the osteoderm tiles to the epidermis and hypodermis, respectively (Fig. 5B) (Krmpotic *et al.*, 2009, 2015).

In the banded shield region of moveable bands, the tiles are arranged slightly differently. In these regions the tiles are elongated and rectangular in shape (Hill, 2006; Krmpotic *et al.*, 2009, 2015). The tiles are connected laterally to their adjacent tile to form a row or band (Fig. 5C), and the tiles of each band imbricate with their anterior and posterior bands (Fig. 5D). That is, the tiles in a given band are overlapped by their anterior tile, and overlay their posterior tile (Hill, 2006; Krmpotic *et al.*, 2009). Accordingly, each tile shows two distinct features: the anterior portion (overlapped part) is smooth and lacks cornified epidermis on its dorsal surface, while the posterior portion (overlapping part) possesses ornaments and cornified scales (Hill, 2006; Krmpotic *et al.*, 2015). The hypodermis is present between the overlapped tiles. Sharpey fibres exist all around the tiles, except on the dorsal surface of the overlapped part (Fig. 5C, D). The medullary cavity in the anterior portion is less developed than in the posterior part, which contains hair follicles, sweat and sebaceous glands (Hill, 2006; Krmpotic *et al.*, 2009, 2015).

Tiles in the banded region are longer than tiles in other regions, but do not exceed 2 or 3 cm. Tile thickness in the banded and non-banded areas does not exceed a few millimeters (Hill, 2006; Krmpotic *et al.*, 2009, 2015).

(b) Integument

The epidermis of the carapace consists of a stratum basale, st. spinosum, st. granulosum, st. lucidum, and st. corneum. The epidermis of neonates is less keratinized and possesses the st. granulosum; however, the st. granulosum regresses during development and is eventually substituted with keratinized epidermis (corneal scales) in adult armadillos. This layer is termed the parakeratotic stratum corneum (Wilson, 1914; Cooper, 1930; Krmpotic *et al.*, 2012, 2014, 2015). The absence of a st. granulosum is seen in other tough and keratinized structures, such as in the hoof wall of the horse (Wattle, 1998; Anon, 2002a; Tomlinson, Mülling & Fakler, 2004).

The integument on the ventral side of armadillos is not ossified, and consists of thick keratinized epidermis containing hairs, sweat glands, and sebaceous glands (Sokolov, 1982; Krmpotic *et al.*, 2012).

As with other bony structures considered herein, the presence of the skin and dermal tissues is essential for osteoderm formation. Autografting of skin onto excised regions of the osteoderm can lead to 'shell' (armour) formation *in situ* (Anderson & Benirschke, 1962).

(3) Functions

(a) Mechanical features

The intricate structure of the armadillo osteoderm makes it an effective armour against predators (Chen *et al.*, 2011), even serving as a bullet-proof shield (Dearden, 2015). Its effectiveness as armour can be attributed to: (i) the cornified epidermis can absorb external forces, and protect the underlying osteoderm (Krmpotic *et al.*, 2014); (ii) the porosity of the tile medulla may allow dissipation of forces (Romanovskaya, Zuev & Khotimskii, 1986; Drake *et al.*, 2016; Zhu *et al.*, 2016) – the osteoderm functions as 'bubble wrap' to deflect shocks; (iii) the compact lamellar bone provides effective resistance; (iv) the segmented structure provides flexibility (Chen *et al.*, 2011; Chintapalli *et al.*, 2014) while reducing the risk of transmission of an injury from one site to the whole shield (in contrast to the non-segmented uniform shells of molluscs in which an injury such as a crack can spread to the whole shell) (Chintapalli *et al.*, 2014); (v) the arrangement in which a tough bony structure (osteoderm) overlies a loose tissue (hypodermis and muscles) results in a cushioning protective effect (Chintapalli *et al.*, 2014); (vi) the joints between the tiles may act in a similar manner to the skull sutures of the goat which can act as hinges in response to impact allowing inflicted forces to be absorbed (Jaslow & Biewener, 1995; Currey, 2010; Drake, 2015).

(b) Thermoregulatory properties

The osteoderm has thermoregulatory roles (Superina & Loughry, 2012; Broeckhoven, du Plessis & Hui, 2017b; Broeckhoven, Mouton & Hui, 2018). Due to its vascular network and the presence of sweat glands, the osteoderm can be used to regulate heat loss. This feature is likely to be important in the tropical habitats of the majority of armadillo species, and given their fossorial behaviour (Superina & Loughry, 2012; Feng *et al.*, 2017). Species inhabiting cooler climates possess long and abundant hairs that insulate the osteoderm, thereby reducing its thermal conductance (Superina & Loughry, 2012; Krmpotic *et al.*, 2015; Feng *et al.*, 2017). In species that inhabit arid habitats, the osteoderm contains a greater number of sebaceous glands whose secretions protect against desiccation (Krmpotic *et al.*, 2015).

(c) Visual impact

The osteoderm and integument cover the majority of the body surface and may contribute to body camouflage. The armour may also mask the presence of topical infections and infestations. For example, leprosy (*Mycobacterium leprae*) infection in the nine-banded armadillo affects the visceral

organs and the integument (Storrs, 1971; Sasaki *et al.*, 1997; Walsh *et al.*, 1999; Fowler & Cubas, 2008; Sharma *et al.*, 2013). However, integumentary lesions in the carapace do not tend to be visible on the external armour (Kirchheimer, Stroks & Binford, 1972; Truman, 2005; Sharma *et al.*, 2013). Given that odd-looking or debilitated animals are targeted by predators (Rudebeck, 1950; Rowley, 1969; Milinski & Löwenstein, 1980; Loehle, 1995; Fleming *et al.*, 2016), the armour may provide a visual defence against predators, corresponding to concealment behaviour (Landeau & Terborgh, 1986; Dixon, 1998).

(4) Sexual differences

Although the osteoderm is present in both sexes of armadillos, there are few data regarding sexual differences in the development of the osteoderm and its tissues. Carapace size appears to be similar in both sexes (Desbiez *et al.*, 2018). This might reflect the absence of male–male combat in armadillos. In the Cape cliff lizard (*Hemicordylus capensis* with), in which there is intrasexual aggression, the osteoderm is sexually dimorphic (Broeckhoven, de Kock & Mouton, 2017a; Broeckhoven *et al.*, 2018). Sexual size dimorphism is uncommon throughout Xenarthra (the superorder that includes armadillos) (Ralls, 1977; Lindenfors, Gittleman & Jones, 2007; Squarcia *et al.*, 2009; Desbiez *et al.*, 2018), and armadillos do not show territorial behaviour (Layne & Glover, 1977; Schell, 1994). A lack of territoriality and combat might thus have removed any selective pressure for sexual dimorphism in armadillo carapace size.

The osteoderm contains minerals and thus could act as a reserve of calcium. However, one study on lactating female armadillos did not identify such a function (Actis *et al.*, 2017). Therefore, it is likely that the primary role of the armadillo osteoderm is for defence.

(5) Other armoured structures in mammals

The armour of the pangolin (*Manis pentadactyla* and *Manis tricuspis*) is non-osseous, instead being composed of keratinous scales that cover the epidermis all over the body except the ventral side (Spearman, 1967; McKittrick *et al.*, 2012; Wang *et al.*, 2016b) with scarce hairs present between the scales (Kawashima *et al.*, 2015). In some mammals such as hedgehogs, tenrecs, echidnas and porcupines, the dorsal and lateral sides of the body are armoured with non-osseous spines (Zherebtsova, 2006; Mori, Maggini & Menchetti, 2014; Gooden & Augee, 2015). The spines have a porous interior overlaid externally by keratin (Vincent & Owers, 1986; Zherebtsova, 2000; Swift *et al.*, 2016). The spines (spurs) on the hindlegs of the male platypus (*Ornithorhynchus anatinus*) and echidna (*Tachyglossus aculeatus*) are also hollow keratinous structures (Whittington & Belov, 2007; Krause, 2010; Ligabue-Braun, Verli & Carlini, 2012).

VII. PENIS BONE/CLITORIS BONE

The penis bone has different names in the literature: baculum, os penis, os priapi, os genitale, penile ossicle, and os glandis. It is believed to support intromission (Thomas, 1915; Ruth, 1934; Lyons, Abernathy & Gropper, 1950; Patterson & Thaler, 1982; Evans & Lahunta, 2013; Schultz *et al.*, 2016b). The os penis occurs in certain groups of mammals such as carnivores (Rinker, 1944; Elder, 1951; Crouch, 1969; Baryshnikov, Bininda-Emonds & Abramov, 2003; Ramm, 2007), ursids (Davis, 1964; Abella *et al.*, 2013), bats (e.g. Vespertilionidae) (Hamilton, 1949; Comelis *et al.*, 2015), rodents (e.g. Muridae) (Ruth, 1934; Wade & Gilbert, 1940; Patterson & Thaler, 1982), insectivores (e.g. Talpidae) (Gredler, 2016) and primates (e.g. Cebidae, Lemuridae) (Dixon, 1987; Dyck, Bourgeois & Miller, 2004; Ramm, 2007). However, in all these groups there are exceptions in which the os penis has not been reported, for example in hyaenids and some viverrids (Baryshnikov *et al.*, 2003), in the bat genera *Cynomops*, *Molossops*, and *Neoplattymops* (Comelis *et al.*, 2018), in Japanese shrew moles (*Urotrichus talpoides*), star-nosed mole (*Condylura cristata*) (Sinclair *et al.*, 2017) and European hedgehog (*Erinaceus europaeus*) (Akbari, Babaei & Goodarzi, 2018), in the primate genera *Tarsius*, *Ateles* and *Lagothrix* and in humans (Dixon, 1987). In marine mammals, cetaceans and Sirenia are reported to lack a penis bone (Miller, 2002; Rommel, Pabst & McLellan, 2007) while pinnipeds such as seals (Scheffer, 1950) and walrus do possess an os penis (Fay, 1982; Miller, 2002).

Marsupials lack an os penis/os clitoris although the epipubic bone (\approx marsupial bone) is suggested to be homologous to the os penis/os clitoris (Jellison, 1945; Kielan-Jaworowska, 1975). The epipubic bones, a pair of bones on the left and right side of the pubic bone, are formed post-natally in marsupials. The epipubic bone together with other pelvic compartments form the pelvic girdle (Nesslinger, 1956). These bones are believed to support the pouch, and to contribute to locomotion. The epipubic bones show sexual size dimorphism: they are larger in females (White, 1989; Reilly & White, 2003; Reilly *et al.*, 2010). Epipubic bones were reportedly present in some early eutherians, and their loss in modern eutherians was hypothesized to be due to the evolution of prolonged gestation removing the need for prolonged external attachment of altricial young (Novacek *et al.*, 1997).

The clitoris bone also has several different names in the literature: baubellum, os clitoris, or os clitoridis. It is found in females of most groups in which males possess the os penis (Rinker, 1944; Scheffer, 1949; Lough-Stevens *et al.*, 2018). The os clitoris is smaller and less developed than the os penis. Androgen administration to females can enhance os clitoris growth to reach a similar size to the os penis of the males (Murakami & Mizuno, 1984; Schultz *et al.*, 2016b; Lough-Stevens *et al.*, 2018).

In other extant classes of vertebrates, a genital bone (with or without a copulatory function) is uncommon (Schulze-Hagen *et al.*, 1995; Marcus, 2011; Brennan & Prum, 2012;

Gredler, 2016; Nasoori, Taghipour & Young, 2018). However, in some reptiles an ossified fraction of the hemipenes and hemiclititoris has been reported (Shea & Reddacliff, 1986; Böhme, 1995; Nunes *et al.*, 2014).

(1) Formation

The process of os penis formation has been studied in most detail in rats and mice. The penis bone in these species arises from the integration of two distinct parts: the proximal and distal segments.

In the late foetal stage (around days 18–20 of gestation), the primordium for the future corpus cavernosum and os penis appears in the distal half of the penis. This primordium, which is composed of mesenchymal cells and is located under the epidermis and above the urethra, is present in both male and female rats (Fig. 6A). However, the mesenchymal cells develop further to form bony tissue exclusively in the male rat. Within the first few days after birth, the proximal segment, which is overlaid by the periosteum, is formed. This segment consists of anterior and posterior parts. The anterior part becomes ossified (membrane bone), and is fused to the posterior part (Fig. 6B) (Ruth, 1934; Glucksmann *et al.*, 1976; Vilmann, 1982; Murakami & Mizuno, 1984, 1986). The posterior part is hyaline cartilaginous tissue which later anchors posteriorly to the corpus cavernosum (Kelly, 2000; Ruberte, Carretero & Navarro, 2017). The posterior part undergoes endochondral ossification in the first week, and is completely ossified by 2–3 weeks after birth (Fig. 6C) (Ruth, 1934; Murakami & Mizuno, 1984, 1986; Ruberte *et al.*, 2017). Around this time, a fibrocartilaginous tissue begins to form in the distal segment. The distal segment is ossified slowly (over up to 8 months) to form non-lamellar bone (Fig. 6D). In the adult, the distal segment is composed of bone and cartilage with hypertrophic chondrocytes (Murakami & Mizuno, 1984; Murakami, 1987a; Yamamoto, 1989).

The process of penile bone formation in mice is very similar to that described above. However, in some strains of mice, the females develop an os clitoridis. In these mice, the primordial cells are formed in the late foetal stage of both sexes. Direct ossification begins soon after birth and produces a single-segment bone in the clitoris that is thought to correspond to the proximal segment of the os penis, although the clitoral bone remains relatively small. Interestingly, in rats, treatment of female neonates with androgens induces the formation of an os clitoridis akin to the male os penis (Glucksmann & Cherry, 1972; Glucksmann *et al.*, 1976; Murakami & Mizuno, 1984; Yang *et al.*, 2010; Ruberte *et al.*, 2017).

In dogs, primordial cell condensation appears in the mid-term foetus at around 35 days. However, the ossification takes place no earlier than the first month after birth. Ossification originates from the cartilaginous foci in the corpus cavernosa. Endochondral ossification begins from the left and right corpus cavernosa in the form of paired rods. Gradually, the ossified rods meet and merge to form a single rod.

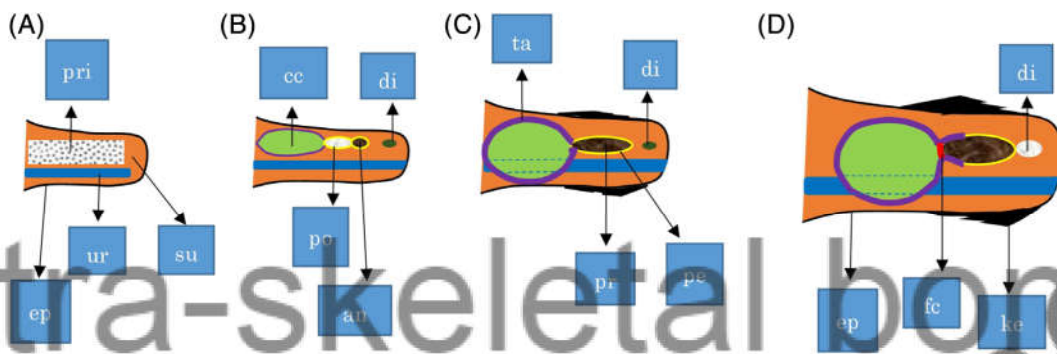
Simultaneously, the periosteum contributes to osteogenesis by adding to the bone mass (appositional growth). The proximal os penis and shaft are both ossified, but the far distal end of the os penis remains cartilaginous. Female dogs normally do not possess a clitoral bone (Kanagasuntheram & Anandaraja, 1960; Meyers-Wallen *et al.*, 1999; Evans & Lahunta, 2013).

Androgens are key regulators of penile bone formation. In addition, interaction between the mesenchymal (primordial) cells and the surrounding tissues (such as the genital tubercle epithelium and the epidermis) are essential for os penis formation (Murakami & Mizuno, 1986; Murakami, 1987b; Kurzrock *et al.*, 1999; Cohn, 2011). Studies on the penile bone in mice showed that *HOX* genes are highly expressed in the baculum-forming cells. Inactivation of *HOX* greatly reduces the size of the os penis and digital bones (Zákány *et al.*, 1997; Perriton *et al.*, 2002; Klonisch, Fowler & Hombach-Klonisch, 2004). Deletion of hind limb enhancer B (*HLEB*) also causes a significant reduction in baculum size (Infante *et al.*, 2015). *HLEB* belongs to the *Tbx4* coding exon, which is an essential component in hindlimb and vascular system development (Menke, Guenther & Kingsley, 2008; Ching *et al.*, 2017). Interestingly, these results demonstrate that genes that contribute to skeletal bone formation also affect penile bone formation.

(2) Structure

(a) Interspecific variation

The os penis or baculum typically is rod shaped (Schultz *et al.*, 2016a). However, its shape and size vary greatly depending on species and even on age of the animal (Friley, 1949; Spornoro, 1992; Ramm, 2007). The baculum can be elongated with a slight curve at the distal end, such as in the dog (Sharir *et al.*, 2011), mink (*Mustela vison*) (Elder, 1951), and river otter (*Lutra canadensis*) (Friley, 1949). It is Y-shaped in some bats (e.g. *Eptesicus furinalis* and *Plecotus austriacus*) (Herdina *et al.*, 2010; Comelis *et al.*, 2015), has a three-pronged end in the muskrat (*Ondatra zibethicus*) (Tasikas *et al.*, 2009), and is wing-shaped in the giant panda (*Ailuropoda melanoleuca*) (Davis, 1964). Its size also shows considerable variation. For example, the baculum can be as small as 0.15 mm in bats (*Eptesicus furinalis*) (Comelis *et al.*, 2015), while in the walrus (*Odobenus rosmarus*) it can reach 489–1040 g, and 476–622 mm in length (about 18% of adult body length) (Fay, 1982). The feline penile bone is much reduced (Jackson, 1902; Yates, 2005): 5–8 mm in the domestic cat (*Felis catus*) (König & Liebich, 2007), 3.8–7.6 mm in the bobcat (*Felis rufus*) (Tumlison & McDaniel, 1984), 3.9–10.2 mm in the mountain lion (*Felis concolor*) (Maser & Toweill, 1984), and 6–9.5 mm in the lion (*Panthera leo*) (Haas, Hayssen & Krausman, 2005). The size and shape of the os penis can be used in species identification and estimation of age (Friley, 1949; Elder, 1951; Schultz *et al.*, 2016a). Although, in general the size of organs is directly related to body size, the length of the penile bone is not strongly correlated with
















	ep: epidermis		pe: periosteum		ke: keratinized epidermis
	su: subcutaneous tissue		cc: corpus cavernosum		ur: urethra
	ta: tunica albuginea		po: posterior part		di: distal part/ cartilage in maturity
	an: anterior part/ bone		pr: proximal segment/ bone		pri: primordium
	* fc: fibrocartilage layer	<u>po and an form the proximal segment (pr)</u>			

Fig. 6. Development of the os penis in the rat (*Rattus norvegicus*) at the distal end of the penis (glans penis). Lateral view. (A) During late pregnancy (≈ 18.5 -day foetus), primordial cells (mesenchymal cells) are present dorsal to the urethra in both male and female rats. In the male this differentiates into the corpus cavernosum, and os penis. (B) During the first week after birth, the proximal part of the os penis forms, which is covered by the periosteum. This part has anterior (bony) and posterior (cartilaginous) regions. These regions are fused together and are adjacent to the corpus cavernosum. The distal part has not yet formed. (C) Between 2 and 3 weeks after birth, the proximal part is ossified to form lamellar bone. The epidermis is keratinized. From the 4th week onwards, the distal part differentiates to form cartilaginous tissue. (D) Maturity (from 10 weeks to 8 months). The distal part undergoes endochondral ossification to become an ossified cartilage. *A thin layer of fibrocartilage (fc) remains between the corpus cavernosum and the posterior region of the proximal os penis in mature rats.

body mass (Lüpold, McElligott & Hosken, 2004; Ramm, 2007; Čanádý & Čomor, 2015; Čanádý & Čomor, 2016; Čsanádý, Duranková & Labancová, 2019). This may be due to the contribution of both growth hormones and androgens to the development of the penile bone (Lyons *et al.*, 1950). Nevertheless, its size is positively correlated with body size in species with polyamorous mating systems. Females of these species tend to prefer to mate with males of larger body size and a larger penis (and thus a larger baculum) (Miller & Burton, 2001; Krawczyk, Malecha & Tryjanowski, 2011). However, correlations between baculum size and body size in different mammalian taxa and whether they are reliable indicators of mate quality still remain a matter of controversy (Schulte-Hostedde, Bowman & Middel, 2011; Čanádý & Čomor, 2016).

(b) The bony compartment

In general, the baculum is located at the distal end of the penis (the glans penis) (Reighard & Jennings, 1966; Yamamoto, 1989; Kelly, 2000; Herdina *et al.*, 2010; Evans & Lahunta, 2013). The baculum is juxtaposed caudally to the corona of the glans (Evans & Lahunta, 2013; Ruberte *et al.*, 2017). The urethra lies parallel to its ventral side (Evans & Lahunta, 2013). In some carnivores, porcupines, and bats there is a groove in the ventral side of the baculum (Dixon, 1995; Atalar & Ceribasi, 2006; Evans & Lahunta, 2013; Comelis *et al.*, 2018). In the dog, this groove is deep, forming a tunnel that protects the urethra (Koch, 1963; Sharir *et al.*, 2011; Evans & Lahunta, 2013; Brassey, Gardiner & Kitchener, 2018). In ursids the groove is superficial (Davis, 1964; Abella *et al.*,

2013) and in the cat the groove is absent (König & Liebich, 2007; Mohammed, 2018).

The os penis is covered by the periosteum. The periosteum is integrated with the tunica albuginea, which emanates from the corpus cavernosum and encloses the os penis and urethra (Wade & Gilbert, 1940; Hill & Kanagasuntheram, 1959; Krölling & Grau, 1960; Bartosiewicz, 2000; Yonezawa *et al.*, 2011; Herdina *et al.*, 2015a,b). Sharpey fibres at the caudal end of the os penis form an anchorage with the corpus cavernosum. These fibres extend through a fibrocartilage plate between the caudal end of the os penis and the corpus cavernosum (Beresford & Burkart, 1977; Kelly, 2000; Herdina *et al.*, 2010, 2015b).

Sharpey fibres attach the cranial end of the baculum to the anterior process in the glans. Several small ligaments have been suggested to serve a similar function (Beresford & Burkart, 1977; Kelly, 2000; Evans & Lahunta, 2013).

The shaft of the baculum is bony, whereas the caudal and cranial ends of the baculum are ossified cartilaginous tissue (Yamamoto, 1989; Rodriguez *et al.*, 2011; Evans & Lahunta, 2013; Phillips *et al.*, 2015). The os penis in the rat, monkey and bat is composed of lamellar bone in the shaft which becomes woven bone near the ends. The medullary cavity is connected to vascularized canals (Herdina *et al.*, 2010; Prakash & Ibrahim, 2018). These canals enter the base (caudal end) of the baculum in the rat (Beresford & Burkart, 1977), while in the bat they mainly enter the ventral side (Herdina *et al.*, 2010). In the dog, beneath the cortical lamellar layer there is a remodelled area filled with secondary osteons and the medullary cavity contains a trabecular region. The cortical lamellar bone in the dog is poorly vascularized (Sharir *et al.*, 2011), in contrast to the well-vascularized lamellar layer of the rat baculum (Kelly, 2000). These features indicate that the baculum has osteological characteristics akin to typical bone.

(c) Integument

The integument of the glans penis is keratinized and becomes cornified and spiny in some species such as bats (Comelis *et al.*, 2018), hedgehogs (Akbari *et al.*, 2018), cats (Krölling & Grau, 1960; Bacha & Bacha, 2012), rats (Patrizi & Munger, 1966; Taylor, Weiss & Komitowski, 1983; Murakami, 1987b), mice (Rodriguez *et al.*, 2011; Phillips *et al.*, 2015) and other rodents (Hooper, 1961; Adebayo *et al.*, 2011). Keratinization and the presence of spines are strongly dependent on androgens (Glucksmann *et al.*, 1976; Johnson, Kitchell & Gilanpour, 1986; Murakami, 1987b; König & Liebich, 2007; Ma *et al.*, 2014). Penile skin in the dog has been reported to be non-keratinized (Shimizu, 1954; Ninomiya & Nakamura, 1981). Penile spines can occur even in species without the penile bone, such as the porcupine (*Hystrix cristata*) (Atalar & Ceribasi, 2006) and hyena (*Crocuta crocuta*) (Drea *et al.*, 2002). These spines function primarily as tactile receptors, and promote friction in the female genital tract (Aronson & Cooper, 1967; Cooper, 1972; Phoenix, Copenhagen & Brenner, 1976; Johnson *et al.*, 1986).

(3) Function

There are two main functions proposed for the os penis. Firstly it may function during intromission to: (i) protect the urethra by deflecting stress forces (Ramm, 2007; Brassey *et al.*, 2018) during the ‘copulatory lock’ in canids (Dixson, 1995) and some primates (Dixson, 1987); (ii) participate in penis erection (Evans & Lahunta, 2013); (iii) stimulate the female genital tract (Ramm, 2007; Sharir *et al.*, 2011); (iv) support the delivery of sperm into the urethra and stabilize copulatory plugs in the female genital tract (Ramm, 2007); (v) facilitate penetration (Kelly, 2000).

Secondly, the os penis may signal male quality: the baculum grows throughout life, and is under the influence of androgens. Therefore, the size and appearance of the penis bone, which will influence penis size and shape, may be an indicator of the quality of the male and may be used by females in mate selection (Friley, 1949; Elder, 1951; Miller & Burton, 2001; Krawczyk *et al.*, 2011; Čanády & Čomor, 2015; Čanády & Čomor, 2016). However, a female preference for penis size has also been reported in species lacking the os penis (Costa, Miller & Brody, 2012; Prause *et al.*, 2015; Hernandez-Jimenez & Rios-Cardenas, 2017).

The clitoris bone (baubellum) usually remains underdeveloped and tends to become smaller with age (Lough-Stevens *et al.*, 2018). Female dogs and rats normally do not develop a clitoris bone, although treatment with androgens (Glucksmann & Cherry, 1972) or sex hormone disorders can induce baubellum formation (Wernham & Jerram, 2006; Evans & Lahunta, 2013; Smeak & Turner, 2014). The function of the baubellum is not known, although it has been suggested that it may have evolved in tandem with the baculum in males (Lough-Stevens *et al.*, 2018).

VIII. OTHER EXTRA-SKELETAL MINERALIZED TISSUES

Heart bones and sesamoids share similarities with the AHOOO extra-skeletal bones discussed in Sections II–VII. In addition, the rhinoceros horn, although being non-osseous (yet partially mineralized), shares similarities with AHOOO structures in terms of its formation, structure and function.

(1) Heart bone (os cordis)

The heart bone is a very small bony fraction found in the ventricular/atrial septum of some ruminants such as sheep (Frink & Merrick, 1974), cattle (James, 1965), camels (*Camelus dromedaries*) (Balah *et al.*, 2014), white-tailed deer (*Odocoileus virginianus*) (Rumph, 1975), and in otters (*Lutra lutra*) (Egerbacher, Weber & Hauer, 2000) and occasionally in elephants (*Elephas maximus*) (Retzer, 1912; Durán *et al.*, 2004). The heart bone develops as the animal grows and is fully formed in adults (Egerbacher *et al.*, 2000; Nabipour & Shahabodini, 2007). It may have two main functions: (i) mechanical support of the atrioventricular area and valves; (ii)

contribution to His bundle alignment (James, 1965; Frink & Merrick, 1974; Nabipour, 2010; Hill & Iazzo, 2015).

There is little information available regarding heart bone formation and its histological origin. Integumentary alterations seem not to be accompanied by os chordis formation, but further investigations are needed to identify any similarities/differences between the os chordis and the AHOOO extra-skeletal bones discussed herein.

(2) Sesamoids

Sesamoids form during embryonic stages. They appear to originate in tendons and/or ligaments, but it has also been suggested that they form as bony fractions that become detached from skeletal bones (Eyal *et al.*, 2015). Mechanical pressure may promote their formation. Sesamoids function in combination with the skeletal system, for example they protect tendons from mechanical stress. The available data do not show an association between sesamoid formation and integumentary alterations (Sarin *et al.*, 1999; Eyal *et al.*, 2015; Samuels, Regnault & Hutchinson, 2017; Abdala *et al.*, 2019). They are not grouped with the AHOOO extra-skeletal bones discussed herein due to major differences in: (i) their origin (tendons); (ii) the role of mechanical factors in their development; (iii) their skeleton-dependent functions; and (iv) the absence of integumentary alterations. However, future investigations should attempt to clarify structural, functional, and evolutionary similarities/dissimilarities between these extra-skeletal bones and the AHOOOs.

(3) Rhinoceros horns

Rhinoceros horns are keratinous rather than bony structures. However, their formation, function, and structure have certain similarities to those of the AHOOO extra-skeletal bones. The African white rhinoceros (*Ceratotherium simum*) (Owen-Smith, 1974) and black rhinoceros (*Diceros bicornis*) (Ritchie, 1963) and the Sumatran rhinoceros (*Dicerorhinus sumatrensis*) (Hubback, 1939; Laurie, 1978) all possess two horns whereas the Indian rhinoceros (*Rhinoceros unicornis*) (Hazarika & Saikia, 2010) and Javan rhinoceros (*Rhinoceros sondaicus*) (Groves & Leslie, 2011) have a single horn.

(a) Formation

The baby is born hornless with the anterior (nasal) horn first becoming visible at around 1–2 months of age in both white and black rhinoceros (Pienaar, Hall-Martin & Hitchins, 1991; Anon, 2019). The posterior (frontal) horn appears at around 1 year in the white rhinoceros, and at 3 months in the black rhinoceros (Anon, 2019). The skin above the primitive growing horn is devoid of hair follicles (Boy *et al.*, 2015). The horn is initiated by filaments from the epidermal basal membrane, located on the underlying dermis, which lie on the periosteum on the frontal and nasal bone (Hieronymus, Witmer & Ridgely, 2006; Boy *et al.*, 2015).

The highest rate of growth takes place in the first year of life (Pienaar *et al.*, 1991; Anon, 2019), after which horn growth slows down over time, but continues throughout life (Rachlow & Berger, 1997; Hieronymus *et al.*, 2006). Growth rate is about 50 mm per year in adult African rhinos (Pienaar *et al.*, 1991).

Rhino horn regrows after falling or dehorning (Blyth, 1868; Bigalke, 1946; Kock & Atkinson, 1993). Dehorning is an anti-poaching policy commonly applied to the rhino (Milner-Gulland, Beddington & Leader-Williams, 1992; Lindeque & Erb, 1995) and involves cutting off the full thickness of the horn body (but not the base). Since there are no blood vessels or innervation in the cut area, this procedure does not cause bleeding or pain. However, since the germinal layer at the base of the horn is undamaged, the horn will regrow eventually reaching its previous size (Bigalke, 1946; Lindeque, 1990; Berger *et al.*, 1993; Kock & Atkinson, 1993; Rachlow & Berger, 1997). Deletion of the germinal layer by methods similar to those used in cattle dehorning would presumably permanently prevent horn regeneration in the rhinoceros.

(b) Structure

Rhinoceros horns are curved and cone-shaped, and are usually present in both sexes (Laurie, 1978; Hieronymus *et al.*, 2006). The anterior horn length is around 578 mm and 472 mm in free-ranging white and black rhinoceros, respectively (Pienaar *et al.*, 1991). In white rhinoceros, the average density of the horn is about 1.30 g/cm² (Rachlow & Berger, 1997).

The horn is composed of keratinous filaments cemented with calcium salts such as hydroxyapatite and melanin (Ryder, 1962; Van Orden & Daniel, 1992; Hieronymus *et al.*, 2006). The horn core is solid and does not have a medullary cavity (Van Orden & Daniel, 1992). The medullary area has a higher density than marginal regions which can be attributed to the high concentration of minerals and melanin in the medulla (Hieronymus *et al.*, 2006).

The base of both anterior and posterior horns is concave, matching bony protrusions on the nasal and frontal bones, respectively (Bigalke, 1946; Ritchie, 1963; Hieronymus & Witmer, 2004; Groves & Leslie, 2011; Gerard *et al.*, 2018). How the domes are formed, whether they are created in association with horn development (Dove, 1935), or by irregular mineralization *in situ* (Hieronymus & Witmer, 2004) or by other mechanisms still remains unclear. Beneath the dome, there is an enlarged nasoconchal sinus that is assumed to provide biomechanical support to allow dissipation of forces and to improve olfaction (Gerard *et al.*, 2018).

The epidermis of the horn consists of three compartments from base to top: (i) basal membrane (the germinal layer); (ii) stratum spinosum; (iii) keratinocyte layers containing corneocytes and long filaments (Boy *et al.*, 2015).

The horn basal membrane is anchored to the underlying tissue *via* Sharpey fibres in the dermis. The fibres pass through the dermis which is thick (about 2–3 cm) and consists

of a dense connective tissue (Hieronymus & Witmer, 2004; Hieronymus *et al.*, 2006; Rothschild, 2013). The dermis provides a blood supply and neural connections to the base of the horn (Boy *et al.*, 2015). In the upper areas of the horn (about 6 cm from the base) there are no blood vessels or neural connections (Kock & Atkinson, 1993). The horn is devoid of hair follicles, and sebaceous and apocrine glands (Boy *et al.*, 2015).

Both sexes of rhinos are horned except for the Javan rhinoceros in which females are either hornless or possess underdeveloped horns (Hubback, 1939; Laurie, 1978; Laurie, 1982; Groves & Leslie, 2011). In African rhinos, the basal circumference of the horn in males is slightly larger than in females (Pienaar *et al.*, 1991; Kock & Atkinson, 1993; Rachlow & Berger, 1997; Berger & Cunningham, 1998), but otherwise the dimensions of the horns are similar in both sexes. In Asian rhinos (Indian and Sumatran), the horn is larger in males (Hubback, 1939; Laurie, 1982).

(c) Function

The rhinoceros is territorial and uses its horns offensively and in defence. Mortality due to intraspecific fights in the black rhino is very high in comparison with other mammals (Berger & Cunningham, 1998; Brett, 1998). Agonistic behaviour has been reported in both sexes of African and Asian rhinos (Ritchie, 1963; Owen-Smith, 1971; Hazarika & Saikia, 2010). The horn can also be used to pull down trees and branches (Hubback, 1939; Van Strien, 1985), or for scratching the ground at salt licks (Ritchie, 1963).

African and Asian rhinos are polygamous (Hutchins & Kreger, 2006; Edwards *et al.*, 2015). Before mating, the male uses various behavioural displays such as puffing and rubbing the horn on the ground, along with horn-to-horn rubbing (Ritchie, 1963; Goddard, 1966; Owen-Smith, 1971). The size of the horn is correlated with dominance in black rhinoceros males (Berger & Cunningham, 1998). Their eyesight is usually considered poor, however, studies on the retina of black and white rhinos revealed that they can see objects of 25–30 cm width from about 100 m distance (Pettigrew & Manger, 2008; Coimbra & Manger, 2017). Therefore, at least in these rhinos, the size of the horns could act as a visual signal. Nevertheless, hornlessness does not affect dominance in black rhino males (Kock & Atkinson, 1993).

Female rhinos use their horns to protect their young and in inter- and intrasexual conflict. African and Asian rhino females are polyandrous. African rhino females may engage in pre-copulatory and post-copulatory conflict with males, in which both sexes sometimes implement their horns (Ritchie, 1963; Goddard, 1966; Owen-Smith, 1974; Laurie, 1978; Berger & Cunningham, 1998; Hutchins & Kreger, 2006). Horn size is not significantly correlated with dominance in black rhino females. It remains controversial whether dehorning compromises maternal defence against predators such as lions and hyenas (Lindeque, 1990; Berger *et al.*, 1993; Berger & Cunningham, 1996; Brain, Forge & Erb, 1999).

Interestingly, Asian rhinos (Indian, Javan and Sumatran) also use their incisor teeth in their agonistic repertoire (Hubback, 1939; Hutchins & Kreger, 2006; Hazarika & Saikia, 2010; Groves & Leslie, 2011). Incisor teeth are absent in African rhinos (Ritchie, 1963; Laurie, 1978; Hillman-Smith *et al.*, 1986).

Because rhino horns are not bony, they are not regarded as AHOOOs in this review. However they do share certain similarities with AHOOOs, including: (i) production of a horn-like structure with considerable mechanical endurance; (ii) keratinization and continuous growth of the keratinized sheath similar to that of the bovid horn; (iii) sinus enlargement during horn development; (iv) partial calcification/mineralization in the horn structure; (v) anchorage of the base to the frontal and nasal bone *via* Sharpey fibres, comparable to the anchorage of osteoderm and the os penis to the peripheral soft tissues; (vi) similar selective forces acting on horns; (vii) behavioural roles of horns in dominance, combat, etc.; (viii) the presence of underlying dermal tissues as the germinal layer that leads to the formation of horns after birth.

The similarities listed above involve the formation, structure and function of the rhino horn. Readers are referred to Prothero & Schoch (2002) for a discussion of the evolution of the rhino skull and horns.

IX. THE DEVELOPMENT OF EXTRA-SKELETAL BONES

(1) Formation of the bone and surrounding tissues

(a) Horns, ossicones and antler pedicle

The primordium of horns, ossicones and antler pedicles is formed before birth. The horn bud, the primitive ossicone, and the antler pedicle arise in subcutaneous connective tissue, in the connective tissue capsule, and under the periosteum, respectively. The horn and ossicone appear to be formed above the periosteum, whereas the antler pedicle is formed underneath the antlerogenic periosteum (AP) and on the frontal bone. The AP contains compartments which are histologically similar to the skeletal bone periosteum (Li & Suttie, 1994, 2001). Note that the periosteum is a fibrous connective tissue (Carlson, 1981; Gilbert, 2003), and thus shares similarities with the connective tissues involved in horn and ossicone formation.

Previous studies have explored the role of the generative layers in horn and pedicle formation. In the horn, the experiments on cattle neonates showed that when the skin and the underlying connective tissues were removed from the horn bud, the horn did not develop. When these excised tissues were grafted elsewhere, a horn developed *in situ*. By contrast, excision and grafting of the horn bud's periosteum did not prevent or cause horn formation *in situ* (Dove, 1935). In the antler, previous studies indicated that AP generates the pedicle below the intact skin and under the influence of androgens. When AP is grafted onto other areas of the body, it

usually generates a pedicle, and when AP is removed, a pedicle is not formed (Goss & Powel, 1985; Goss, 1987, 1991; Li, Harris & Suttie, 2001; Li *et al.*, 2007a). However, in some cases, despite removal of the AP from the pedicle site, the pedicle and antler developed normally (Goss & Powel, 1985). Disbudding of juvenile (5–7 months) male red deer with the same technique used for cattle inhibits antlerogenesis (Hamilton, Kyle & Robson, 1993). This and other studies (Goss & Powel, 1985; Goss, 1987, 1991; Li *et al.*, 2001, 2007a, 2007b) clearly indicate that interactions between the skin and the underlying tissue are essential for pedicle formation. It must be noted that these studies involving AP removal and grafting were conducted on animals with primitive pedicles present.

In deer, AP differentiation takes place in a time-dependent manner under the influence of testosterone concentration and body mass (Li *et al.*, 2003). Therefore, the generative features of AP become functional much later than the generative tissues of horns and ossicones. Comparison of the AP in red deer with that of reindeer, whose antlers develop soon after birth, could help us to understand the chronological pathway of AP differentiation. The mechanisms involved in pedicle primordium differentiation are not yet understood. Likewise, the mechanisms that trigger horn/ossicone generative layers to form have yet to be explored.

(b) Events in the skin and underlying tissues

(i) *Skin.* Disorders of the skin's underlying tissues may affect the bone. For example, in osteogenesis imperfecta, genes that contribute to collagen type I synthesis are mutated, thereby compromising both the dermis and bones (Chien, Mu & Sewon Kang, 2013). The skin has an important role in repair of the underlying tissues and it is also important in bone regeneration (Hirata *et al.*, 2003; Nasoori & Hoomand, 2017; Nasoori, 2018). The presence of an epidermal cap is required for lizard tail regeneration (Lozito & Tuan, 2015, 2017) and an epidermal signal and skin interactions are involved in bone regeneration in zebrafish (Armstrong *et al.*, 2017; Iwasaki *et al.*, 2018).

(ii) *Epithelial–mesenchymal transition.* During embryonic development, neural tube and somites, which make up transient embryonic epithelia, generate neural crest progenitors. Neural crest cells are multipotent and motile, and differentiate to form various types of cells such as neurones, bone and cartilage cells (Theveneau & Andrieu, 2015; Ahlstrom & Erickson, 2009; Strobl-Mazzulla & Bronner, 2012; Nitzan & Kalchauer, 2013). This epithelial–mesenchymal transition is involved in horn (Capitan *et al.*, 2011, 2012; Allais-Bonnet *et al.*, 2013) and os penis formation (Murakami & Mizuno, 1986; Murakami, 1987b; Kurzrock *et al.*, 1999). This mechanism has also been proposed for osteoderm formation in American alligators (Dubansky & Dubansky, 2018). Epithelial–mesenchymal transition may define crucial mechanisms that regulate AHOOO formation.

Wang *et al.* (2019) reported that the formation of 'headgear' in pecoran ruminants shares similar gene expression

profiles, which mainly originate in nerve, bone, and skin tissues. They showed that neural crest stem cells had an essential role. Wang *et al.* (2019) also discuss the phylogenomic relationships of horns and antlers among pecoran ruminants. Buitrago-Delgado *et al.* (2015) noted that neural crest stem cells retain their pluripotency even after most mesoderm cells are lineage restricted. Hall (2018), discussing fin skeleton and scale formation, speculated that neural crest cells have pluripotency (stemness) features.

Neural crest stem cells usually differentiate during embryo organogenesis. Is it possible that these cells exist in mature individuals, or that cell lineages in mature individuals differentiate into neural crest cells? There is some evidence for the presence of neural crest cells in adult human tissues such as the periodontal ligament (Pelacz, Huang & Cheung, 2013; Yam *et al.*, 2018; Tomokiyo, Wada & Maeda, 2019), and adult human gingiva-derived mesenchymal stem cells may be able to differentiate into neural crest cells (Zhang *et al.*, 2018a).

For the AHOOO extra-skeletal bones, it may be that a sub-population of neural crest cells remain undifferentiated for a certain period (perhaps the late foetal stage, around birth or after puberty), after which particular cues (such as hormones, growth factors, etc.) stimulate them to resume differentiation. This suggestion has not been explored, but it is in agreement with Wang *et al.* (2019, p. 2) who stated that, in horned ruminants 'specific regulatory elements may also play a role in reprogramming neural crest cells to develop into headgear'. It is also possible that other cells such as endothelial cells participate in epithelial-to-mesenchymal transition (Shoshani & Zipori, 2011).

Apart from during embryonic development, epithelial–mesenchymal transitions occur in tissue healing and in cancer (Ribatti, 2017). Experiments in which AP was grafted underneath the foreleg skin of deer showed that wounding of the grafted site encouraged antlerogenesis (Goss & Powel, 1985; Goss, 1991). This suggests that tissue healing could be involved in pathways conducive to antler formation. In addition, oncogenic pathways can cause rapid growth of antlers, however, 'some tumor suppressor genes are under strong selection in deer' (Wang *et al.*, 2019, p. 1). Whether or not similar mechanisms (such as different epithelial–mesenchymal transition pathways) are recruited in the formation of horns, ossicones, osteoderm, and the os penis/os clitoris remains to be explored.

(2) Postnatal ossification

Ossification of the extra-skeletal bony structures considered herein takes place after skeletal bone formation, i.e. mainly after birth. Post-natal ossification is also found in other structures, such as the permanent teeth (Spinage, 1973; Honda *et al.*, 2008; Almonaitiene, Balciuniene & Tutkuvienė, 2010). The process of ossification continues in some areas of the skeleton even after birth, for example, fusion of the skull sutures (Moss, 1958; Madeline & Elster, 1995; Sun, Lee & Herring, 2004; Wang, Strait & Dechow, 2006),

ossification of the epiphyseal plate (Crowder & Austin, 2005; Emons *et al.*, 2011), and ossification of the middle ear (Saunders, Kaltenbach & Relkin, 1983; Yokoyama *et al.*, 1999; Richard *et al.*, 2017). The occurrence of post-natal bone formation in AHOOO extra-skeletal bones may provide useful insights into the development and regeneration of bone that may have implications in the field of regenerative medicine.

X. FUTURE DIRECTIONS

- (1) The AHOOO extra-skeletal bones originate in the connective tissues of the subcutaneous/dermal regions. The physiological cues (such as hormones, growth factors, etc.) and environmental cues (e.g. ambient temperature) that induce/stimulate osteogenesis and epidermal alteration remain to be elucidated.
- (2) The involvement of neural crest cells and epithelial–mesenchymal transition pathways in AHOOO formation remain to be studied in detail. Histological and immunohistochemistry studies on samples from the budding sites could reveal the mechanisms involved in AHOOO formation.
- (3) Integumentary alterations take place in tandem with ossification *in situ*. Still, it is not clear whether these integumentary alterations are under the influence of the underlying bone formation or whether these processes take place spontaneously.
- (4) The mechanisms that lead to sinus enlargement and pneumatization during headgear formation have not been investigated in detail. Investigations of differences between skull formation in horned and hornless (polled) pecoran ruminants, and evaluation of the influence of dermal tissue on sinus enlargement could reveal the key elements involved.
- (5) Some of the phenomena discussed herein should be investigated in more detail, including: (i) multiple horn structures; (ii) ‘dead’ bones; (iii) secondary bone formation; (iv) pronghorn formation with a focus on the site of the horn before and after birth; (v) the type of ossification in bovid horns, antilocaprid horns, and Giraffidae ossicones, and the role of the frontal periosteum in ossification; and (vi) sexual dimorphism in armadillo osteoderm.
- (6) AHOOOs are found in very different mammalian taxa (Table 1). Previous work has analysed the phylogenomic profile of ‘headgear’ among horned ruminants in the order Artiodactyla (Wang *et al.*, 2019), and species of the family Dasypodidae have relatively similar armour. The present review does not attempt to prove that AHOOOs have evolved as a single class of structures in extant mammals. In fact, they are likely to have evolved (been lost or gained) due to different selective pressures. An evolutionary assessment of

Table 1. Distribution of extra-skeletal structures in eutherian mammal taxa

Extra-skeletal bone	Family	Order
Osteoderm	Dasypodidae	Cingulata
Antlers	Cervidae	Artiodactyla
Horns	Bovidae	Artiodactyla
Pronghorns	Antilocapridae	Artiodactyla
Ossicones	Giraffidae	Artiodactyla
Os penis/os clitoris	Canidae, Fleidae, Mustelidae, Ursidae	Carnivora
	Vespertilionidae	Chiroptera
	Talpidae	Soricomorpha
	Muridae	Rodentia
	Cebidae, Lemuridae	Primates

AHOOOs will require extensive future work, and is beyond the scope of this review. While previous studies have comprehensively evaluated evolutionary features of headgear, osteoderm, and genital bones, additional comprehensive studies are warranted to cover the evolution of the broad range of extra-skeletal bony structures in mammals.

- (7) Dermal components and the integument are both essential in the formation, structure and functions of AHOOOs. Thus, future studies could investigate the evolution of the integumentary system and its role in AHOOO structures. Palaeontological studies are usually based on hard tissues such as bones, which thus form a cornerstone of evolutionary assessment. Evaluation of integumentary alterations, and the natural selection of bony structures that originate in the dermis of extant mammals, could open up new avenues for understanding the evolution of AHOOOs. Such studies may provide insights into extinct taxa which possessed similar structures, such as the horn-like apparatus of Mylagaulidae (Hopkins, 2005) and Dinocerata (Marsh, 1873), or the dermal bones of extant sloths (McDonald, 2018).

XI. CONCLUSIONS

- (1) Primordial cells are present *in situ* within the foetal stages. These act as germinal foci that contribute to postnatal ossification and integumentary alterations. Neural crest cells, through epithelial-to-mesenchymal transition, are thought to play a crucial role in the formation of extra-skeletal bones and the accompanying tissues such as nerves and skin.
- (2) Ossification takes place after birth in the subcutaneous region/dermis.
- (3) Epidermal changes are accompanied by underlying bony structure formation.

(4) Extra-skeletal bony structures vary between the sexes in some species. Ossification is restricted to males in deer antlers (except reindeer), the horns of some bovids, the okapi's ossicones, and the os penis. Ossification occurs in both sexes in reindeer antlers, in the horns of some bovids, in pronghorns, in giraffe ossicones, and in armadillo osteoderm. An os clitoris is found in some mammalian species in which the males possess an os penis.

(5) Keratinization/cornification is associated with bone formation. Keratinization may or may not be restricted to males, similarly to the pattern of ossification.

(6) The protrusion that occurs on the roof of the skull is associated with underlying sinus enlargement in horns, ossicones, and rhino horns. The enlarged sinus provides mechanical support for the overlying bony/keratinous structure.

(7) The outer layer of the bony compartment is mainly composed of compact bone, while the inner areas are spongy and trabecular.

(8) The bony structures are well vascularized and have a medullary cavity. Rhino horn is a keratinous structure, is solid and lacks the medullary cavity.

(9) There may be gradients in compactness of the bony structures involving: (i) compact and trabecular bone alignment; (ii) presence of a medullary cavity; and (iii) secondary ossification (in ossicones and osteoderm) to boost mechanical resistance.

(10) The contrast in toughness between the bony compartment and its surrounding tissues may function to dissipate mechanical stress on the bone. The enlarged sinus spaces under horns and ossicones, the hard keratinous integument in horns and osteoderm, adjacent soft tissue under the osteoderm, the presence of the (soft) corpus cavernosum behind the baculum, and the presence of cartilaginous ends in the baculum, all attenuate the forces inflicted on AHOOO structures.

(11) The integument and its keratinous apparatus have crucial roles in the generation and protection of the underlying bony structure.

(12) The bony structures provide an anchorage to their underlying/adjacent tissues. Horns and ossicones are fused to the skull roof; deer antlers root in the pedicle, which is fused to the skull; armadillo osteoderm and the os penis are anchored *via* Sharpey fibres to the surrounding soft tissues. Sharpey fibres also anchor rhinoceros horns by adhering to the horn base to the frontal and nasal bones.

(13) AHOOOs have three major functions: (i) mechanical fortification enabling the animals to fight, defend and forage; (ii) visual impact to provide social dominance, attract mates, create andromimicry in females, and in concealment; (iii) thermoregulation through a vascular network which facilitates heat loss.

XII. REFERENCES

ABBA, A. & SUPERINA, M. (2010). The 2009/2010 armadillo red list assessment. *Edentata* **11**, 135–185.

- ABDALA, V., VERA, M. C., AMADOR, L. I., FONTANARROSA, G., FRATANI, J. & PONSSA, M. L. (2019). Sesamoids in tetrapods: the origin of new skeletal morphologies. *Biological Reviews* **94**, 2011–2032.
- ABELLA, J., VALENCIANO, A., PÉREZ-RAMOS, A., MONTOYA, P. & MORALES, J. (2013). On the socio-sexual behaviour of the extinct ursid *Indarctos arctoides*: an approach based on its baculum size and morphology. *PLoS One* **8**, e73711.
- ACTIS, E., MOSCONI, S., JAHN, G. & SUPERINA, M. (2017). Reproductive implications of bone mineral density in an armadillo, the pichi (*Zaedyus pichii*). *Journal of Mammalogy* **98**, 1400–1407.
- ADEBAYO, A. O., AKINLOYE, A. K., OLURODE, S. A., ANISE, E. O. & OKE, B. O. (2011). The structure of the penis with the associated baculum in the male greater cane rat (*Thryonomys swinderianus*). *Folia Morphologica* **70**, 197–203.
- AHSTROM, J. D. & ERICKSON, C. A. (2009). The neural crest epithelial-mesenchymal transition in 4D: a tail of multiple non-obligatory cellular mechanisms. *Development* **136**, 1801–1812.
- AHN, S. H., KIM, J. H., CHO, Y. Y., SUH, S., KIM, B. J., HONG, S., LEE, S. H., KOH, J. M. & SONG, K. H. (2019). The effects of cortisol and adrenal androgen on bone mass in Asians with and without subclinical hypercortisolism. *Osteoporosis International* **30**, 1059–1069.
- AKBARI, G., BARBAEI, M. & GOODARZI, N. (2018). The morphological characters of the male external genitalia of the European hedgehog (*Eristaceus europaeus*). *Folia Morphologica* **77**, 293–300.
- ALLAIS-BONNET, A., GROHS, C., MEDUGORAC, I., KREBS, S., DJARI, A., GRAF, A., FRITZ, S., SEICHTER, D., BAUR, A., RUSS, L., BOUET, S., ROTHAMMER, S., WAHLBERG, P., ESOUERRE, D., HOZE, C., et al. (2013). Novel insights into the bovine polled phenotype and horn ontogenesis in Bovidae. *PLoS One* **8**, e63512.
- ALMONATHIENE, R., BALCIUNIENE, I. & TUTKUVIENE, J. (2010). Factors influencing permanent teeth eruption. Part one-general factors. *Stomatologija* **12**, 67–72.
- AL-SOBAYIL, F. (2007). A new simple device for dehorning in small ruminants. *Small Ruminant Research* **67**, 232–234.
- ALVAREZ, F. (1995). Functional directional asymmetry in fallow deer (*Dama dama*) antlers. *Journal of Zoology* **236**, 563–569.
- ANDERSON, J. & BENIRSCHKE, K. (1962). Tissue transplantation in the nine-banded armadillo, *Dasypus novemcinctus*. *Annals of the New York Academy of Sciences* **99**, 399–414.
- Anon (2002a). The hoof. Histology Part 2 Index. Oklahoma State University. Electronic file available at <https://instruction.cvhs.okstate.edu/Histology/HistologyReference/HRHoofframe.htm> Accessed 24.02.2020.
- Anon (2002b). The integument- the skin and all of its derivatives. Histology Part 2 Index. Oklahoma State University. Electronic file available at <https://instruction.cvhs.okstate.edu/Histology/HistologyReference/hrskin.htm> Accessed 24.02.2020.
- Anon (2019). How rhino horn grows. Rhino Conservation Botswana. Electronic file available at <https://rhiniconservationbotswana.com/how-rhino-horn-grows/> Accessed 24.02.2020.
- APOSTOLAKI, N., RAYFIELD, E. & BARRETT, P. (2015). Osteological and soft-tissue evidence for pneumatization in the cervical column of the ostrich (*Struthio camelus*) and observations on the vertebral columns of non-volant, semi-volant and semi-aquatic birds. *PLoS One* **10**, e0143834.
- ARMSTRONG, B. E., HENNER, A., STEWART, S. & STANKUNAS, K. (2017). *Shh* promotes direct interactions between epidermal cells and osteoblast progenitors to shape regenerated zebrafish bone. *Development* **144**, 1165–1176.
- ARONSON, L. R. & COOPER, M. L. (1967). Penile spines of the domestic cat: their endocrine-behavior relations. *The Anatomical Record* **157**, 71–78.
- ASHTON, E. & ZUCKERMAN, S. (1956). Cranial crests in the Anthropoidea. *Proceedings of the Zoological Society of London* **126**, 581–634.
- ATALAR, O. & CERIBASI, A. O. (2006). The morphology of the penis in porcupine (*Hystrix cristata*). *Veterinarni Medicina (Praha)* **51**, 66.
- ATHA, J., YEADON, M., SANDOVER, J. & PARSONS, K. (1985). The damaging punch. *BMJ* **291**, 1756–1757.
- AUBRY, P. (2005). Routine surgical procedures in dairy cattle under field conditions: abomasal surgery, dehorning, and tail docking. *Veterinary Clinics of North America: Food Animal Practice* **21**, 55–72.
- AVMA (2014). Literature review on the welfare implications of the dehorning and disbudding of cattle, American Veterinary Medical Association. Electronic file available at <https://www.avma.org/KB/Resources/LiteratureReviews/Pages/Welfare-Implications-of-Dehorning-and-Disbudding-Cattle.aspx> Accessed 24.02.2020.
- BA, H., WANG, D., WU, W., SUN, H. & LI, C. (2019a). Single-cell transcriptome provides novel insights into antler stem cells, a cell type capable of mammalian organ regeneration. *Functional & Integrative Genomics* **19**, 555–564.
- BA, H., WANG, D., YAU, T. O., SHANG, Y. & LI, C. (2019b). Transcriptomic analysis of different tissue layers in antler growth Center in Sika Deer (*Cervus nippon*). *BMC Genomics* **20**, 173.
- BACHA, J. & BACHA, L. (2012). *Color Atlas of Veterinary Histology*, pp. 127, 227–127, 237. John Wiley & Sons, Iowa.